Oral Radiol (2013) 29:70–73
DOI 10.1007/s11282-012-0101-5

CASE REPORT

Radicular dens invaginatus in a mandibular premolar: cone-beam computed tomography findings of a rare anomaly

Frederico Sampaio Neves · Andréa dos Anjos Pontual · Paulo Sérgio Flores Campos · Marco Antônio Gomes Frazão · Solange Maria de Almeida · Flávia Maria de Moraes Ramos-Perez

Received: 2 April 2012 / Accepted: 26 May 2012 / Published online: 21 August 2012

Abstract Dens invaginatus is a rare developmental anomaly and its etiology remains controversial. Radicular dens invaginatus is an unusual dental anomaly. The aims of this paper are to report the radiographic and tomographic findings of a case of radicular dens invaginatus and to discuss the relevant features associated with this dental anomaly. A 16-year-old female was referred to a private oral radiology clinic for orthodontic evaluation. Radiographically, a morphological alteration to the root portion of the right mandibular first premolar and the presence of a discrete radiolucent periapical lesion were observed. The diagnosis was only elucidated after cone-beam computed tomography (CBCT). The CBCT images revealed enlargement of the root, and a dilated invagination with limited enamel that had its open site along the lateral portion of the root without evidence of buccal and lingual expansion. The diagnosis of radicular dens invaginatus was then established.

Keywords Dens invaginatus · Cone-beam computed tomography · Dental anomaly

F. S. Neves (✉) · M. A. G. Frazão · S. M. de Almeida
Department of Oral Diagnosis, State University of Campinas, Piracicaba Dental School, Av Limeira, 901, Areião, Piracicaba, SP 13414-903, Brazil
e-mail: fredsampaio@yahoo.com.br

A. dos Anjos Pontual
Department of Oral Diagnosis, School of Dentistry, Pernambuco University, Av Gal Newton Cavalcanti, 1650, Camaragibe, Recife, PE, Brazil

P. S. F. Campos
Department of Oral Radiology, School of Dentistry, Federal University of Bahia, Av Araújo Pinho, 72, Canela, Salvador, BA, Brazil

F. M. de Moraes Ramos-Perez
Department of Oral Radiology, School of Dentistry, Federal University of Pernambuco, Cidade Universitária, Av Professor Moraes Rego, 1235, Recife, PE, Brazil

Introduction

Dens invaginatus (DI), also known as dens in dente, dentoid in dente, dilated gestant odontome, and dilated composite odontome, is a rare developmental anomaly, and its etiology remains controversial. Several theories have been proposed, including alterations in tissue pressure, trauma, infection, or local discrepancy in cellular hyperplasia [1].

Coronal and radicular varieties can be associated with DI. The basic difference between these two varieties lies in the site of origin of the invagination process, which constitutes the essential part of the anomaly. In the coronal variety, the developmental anomaly results from a deepening or invagination of the enamel organ into the interdental papilla prior to calcification of the dental tissues [2]. The invagination process of the radicular variety results from enfolding of Hertwig's sheath and thus has its origin within the root after crown development has been completed [3].

Most of the available data for this pathology come from case reports and the information remains limited, which makes it important to report further information for delineation of the profile of the condition. Thus, the aims of this article are to report the radiographic and tomographic findings of a case of radicular DI and to discuss the relevant features associated with this dental anomaly.

Fig. 1 Panoramic radiography showing a morphologic alteration in the radicular portion of the right mandibular first premolar

Fig. 2 Periapical radiography showing a normal crown with a radicular malformation extending from the cervical third to the apex

Case report

A 16-year-old female was referred to an oral radiology clinic to undergo imaging examinations for orthodontic treatment planning. Panoramic radiography revealed a morphologic alteration in the radicular portion of the right mandibular first premolar and the presence of a discrete periapical radiolucent lesion (Fig. 1). Periapical radiography revealed a normal crown with a radicular malformation extending from the cervical third to the apex, with probable involvement of the pulp chamber and root canals, beyond the presence of a diffuse periapical lesion (Fig. 2).

To clarify and establish a conclusive diagnosis, the patient was examined using a Classic i-CAT CBCT unit (Imaging Sciences International Inc., Hatfield, PA, USA) operating at 120 kVp and 8 mA, with a voxel size of 0.25 mm and a field of view of 8 cm. In the slice parallel to the dental arch, it was possible to visualize a radicular malformation with heterogeneous density (similar to enamel, dentin, and pulp) inside, with an evident communication between the invagination and the root surface (Fig. 3). The crown had a normal aspect and did not exhibit any cortical expansion. A periapical radiolucent lesion was observed in the apical third of the tooth with a slight extension to the buccal side, without root resorption of the tooth (Fig. 3). On the basis of these findings, a diagnosis of radicular DI was obtained.

Discussion

Two distinct types of radicular DI were described by Oehlers [3]. The first type involves an axial enfolding of the wall of a root, indicating an incomplete attempt at root bifurcation. This type does not change its clinical characteristics common to the other forms of DI, and it has been suggested that it should be classified as a variation of the root morphology. The second type is a true DI, which presents as an enamel-lined invagination within the root originating at an opening on the root. On the basis of the CBCT findings, the present case was the second form of root invagination described by Oehlers [3] and, according to this author, this is the only type for which the term "radicular DI" is appropriate.

A PubMed search was conducted (including articles published in the English literature; Table 1) to review the literature for case reports of radicular DI. The search used the keywords "radicular DI", "radicular dilated composite odontome", "radicular gestant odontome", and "radicular dens in dente". In all the selected articles, the characteristics of radicular DI were confirmed. Five previous cases of radicular DI have been described. However, it is noted that only our case involved the use of CBCT to define the diagnosis.

According to Payne and Craig [6], radicular DI is normally expected to show evidence of a communication

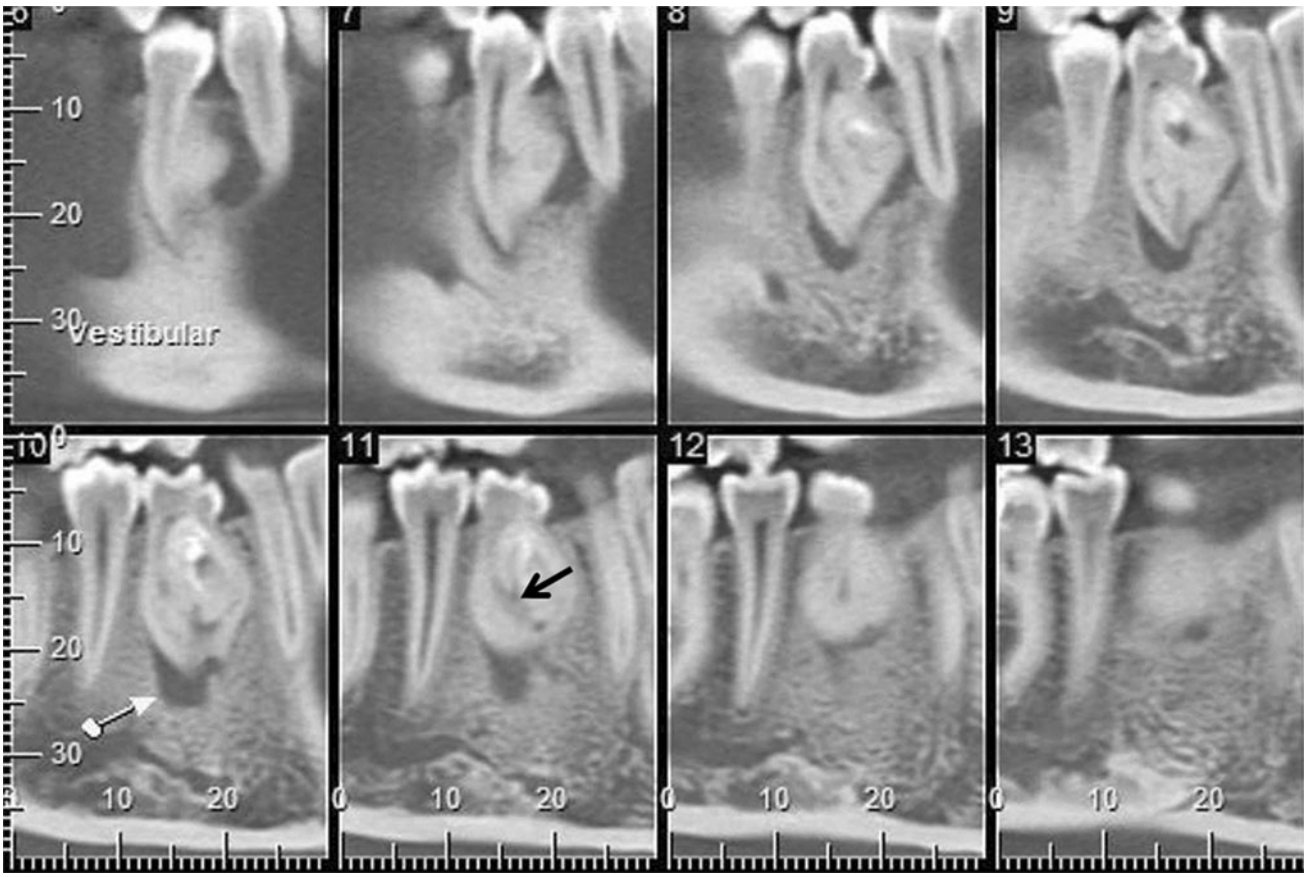

Fig. 3 A slice parallel to the dental arch of CBCT showing a radicular malformation with heterogeneous density inside and evident communication between the invagination and the root surface (*black arrow*). A large periapical lesion can also be seen (*white arrow*)

Table 1 Case reports of radicular DI

References	Case number	Teeth	Imaging modality	Presence of periapical lesion
Oehlers [3]	1	22	Periapical radiography	Yes
Bhatt and Dholakia [5]	2	34	Periapical radiography	Yes
Soames and Kuyebi [6]	3	12	Not available	Yes
Payne and Craig [4]	4	38	Periapical radiography	Yes
Pandey and Pandey [7]	5	14	Periapical radiography	Not available
Neves et al. (present case)	6	44	CBCT, periapical and panoramic radiography	Yes

between the invagination and the root surface, owing to the proliferation and ingrowth of Hertwig's sheath into the dental papilla. In the slice parallel to the dental arch of CBCT, this communication was easily visualized.

Some clinical cases have been related to a combination between DI and other dental anomalies, such as short roots, microdontia, taurodontism, obliterated pulp chambers [8], gemination, supernumerary teeth, and dentinogenesis imperfecta [9]. However, no such associations were observed in the present case.

Clinically, several pulpal (sensitivity to percussion and necrosis) and periodontal (presence of a periodontal pocket) alterations as well as dental mobility and the presence of a sinus track can be associated with DI. Radiographically, it can be observed that radicular DI shows an uncommon morphology of the root, as well as the presence of a periapical lesion (Table 1), and an increasing size of the pulpal chamber and root canal finishing with two apexes [10]. In conventional radiographies, it is not always possible to determine the relationship between the invaginated portion of the tooth and the chamber and/or root canals with high precision. In the present case, three-dimensional CBCT images made it possible to observe the communication between the pulpal and periodontal spaces, resulting in a large and diffuse periapical lesion.

Teeth with an invagination are more susceptible to carious lesions as a consequence of the pulpal topography, which serves as a retention material, as well as structural defects in these areas where the enamel is badly formed or absent. Numerous thin canals allow communication with the pulp, making it possible for microorganisms and their products to reach the pulp, thereby leading to pulpal infection and necrosis [1, 2]. Consequently, microscopic examination of decalcified sections is performed to confirm that radicular DI has a communication with the oral cavity, without communication with the occlusal enamel, thus allowing irritants and microorganisms to enter directly into the pulpal cavity, including the area that is separated from the pulpal tissue by a thin enamel layer and dentine. This condition commonly leads to necrosis of the adjacent pulpal tissue and to the development of periapical lesions soon after the tooth eruption [5, 6]. We believe that this was a possible cause of the periapical lesion in the present case.

According to Pandey and Pandey [7], endodontic treatment of radicular DI is not indicated because the amount of disturbing force exerted by a tooth of this size on the supporting structures disturbs the normal anatomy. Extraction of the tooth is one of the most suitable modalities.

Cone-beam computed tomography is a useful tool for the management of complex endodontic problems, because it enables us to acquire three-dimensional information on the morphology of root canals, teeth, and surrounding tissues under lower radiation exposure compared with multidetector computed tomography [11]. In the diagnosis of DI, this imaging modality provides many benefits, such as a sharp, focused, and three-dimensional view of the invagination, and also allows the visualization of different tissues and canals in the root.

Conclusions

Such cases always pose a challenge to clinicians regarding the diagnosis as well as the treatment. Owing to the intrinsic limitations of conventional radiographies, they cannot reveal the detailed characteristics of DI, such as the type and extent. In our case, CBCT was fundamental to the final diagnosis.

Conflict of interest The authors declare that they have no conflict of interest.

References

1. Hülsmann M. Dens invaginatus: aetiology, classification, prevalence, diagnosis, and treatment considerations. Int Endod J. 1997;30:79–90.
2. Bishop K, Alani A. Dens invaginatus. Part 1: classification, prevalence and aetiology. Int Endod J. 2008;41:1123–36.
3. Oehlers FA. The radicular variety of dens invaginatus. Oral Surg Oral Med Oral Pathol. 1958;11:1251–60.
4. Bhatt AP, Dholakia HM. Radicular variety of double dens invaginatus. Oral Surg Oral Med Oral Pathol. 1975;39:284–7.
5. Soames JV, Kuyebi TA. A radicular dens invaginatus. Br Dent J. 1982;152:308–9.
6. Payne M, Craig GT. A radicular dens invaginatus. Br Dent J. 1990;169:94–5.
7. Pandey SC, Pandey RK. Radicular dens invaginatus—case report. J Indian Soc Pedod Prev Dent. 2005;23:151–2.
8. Desai RS, Vanaki SS, Puranik RS, Rashmi GS, Nidawani P. A unusual combination of idiopathic generalized short-root anomaly associated with microdontia, taurodontia, multiple dens invaginatus, obliterated pulp chambers and infected cyst: a case report. J Oral Pathol Med. 2006;35:407–9.
9. Canger EM, Celenk P, Sezgin OS. Dens invaginatus on a geminated tooth: a case report. J Contemp Dent Pract. 2007;8:99–105.
10. Demartis P, Dessì C, Cotti M, Cotti E. Endodontic treatment and hypotheses on an unusual case of dens invaginatus. J Endod. 2009;35:417–21.
11. Patel S, Kanagasingam S, Mannocci F. Cone beam computed tomography (CBCT) in endodontics. Dent Update. 2010;37:373–9.