

Leishmania mexicana: Immunology and Histopathology in C3H Mice

GABRIEL GRIMALDI, JR.,*¹ PAMELA LANE MORIEARTY,*² AND RODNEY HOFF†

*Department of Pathology and †Harvard/Wellcome/PAHO/UFba Project, Federal University of Bahia, Salvador, Brazil

(Accepted for publication 20 November 1979)

GRIMALDI, G., JR., MORIEARTY, P. L., AND HOFF, R. 1980. *Leishmania mexicana*: Immunology and histopathology in C3H mice. *Experimental Parasitology* 50, 45-56. C3H mice were infected subcutaneously with 10⁵ promastigotes of *Leishmania mexicana* and subsequent lesions were examined at 3, 5, and 8 months. All animals developed persistent nonulcerating nodules of variable size which did not metastasize. The nodules contained amastigotes with a mononuclear infiltrate of histiocytes, lymphocytes, and plasma cells, but without formation of tuberculoid-type granulomas. Neutrophils and eosinophils were also encountered in some cases. Specific antileishmanial antibodies and delayed-type hypersensitivity to leishmanial antigen were present at 3, 5, and 8 months postinfection. *L. mexicana* infection in C3H mice differs from classic self-healing cutaneous leishmaniasis by the persistence of nonhealing, nonulcerating, nonmetastasizing lesions, despite evidence of cellular and humoral immunity.

INDEX DESCRIPTORS: *Leishmania mexicana*; Protozoa, parasitic; Hemoflagellate; Mice, C3H; Leishmaniasis, cutaneous; Immunofluorescence; Indirect hemagglutination; Delayed hypersensitivity; Ear thickness test; Histopathology.

INTRODUCTION

Several experimental models of leishmaniasis have been developed which attempted to reproduce the disease as it occurs in man. These models, including both the cutaneous and visceral forms, are of considerable value in studies on the cellular and humoral mechanisms of immunity to *Leishmania* (Preston and Dumonde 1976). The course of *Leishmania* infection in the mouse varies considerably depending not only on the parasite species, but also on host genetic factors. For example, different strains of inbred mice vary in their response to infection with *L. tropica* (Preston and Dumonde 1976), *L. mexicana* (Perez *et al.* 1978), and *L. donovani* (Bradley and Kirkley 1977), thus suggesting that innate

susceptibility or resistance to the parasite is genetically controlled (Bradley 1977).

L. mexicana normally infects sylvatic mammals, producing a relatively innocuous disease with occasional moderate cutaneous lesions (Lainson and Shaw 1978). In man, *L. mexicana* produces cutaneous lesions that are initially nodular, then ulcerative, and may or may not resolve spontaneously (Lainson and Strangeways-Dixon 1963). In some cases, especially when the site of infection is the ear, the lesions become persistent, forming the characteristic "chiclero's ulcer" (Preston and Dumonde 1976). In most strains of laboratory mice, the lesions develop progressively (Coelho and Coutinho-Abath 1965; Mata *et al.* 1968; Alexander and Phillips 1978a, b). The lesions appear as tumor-like nodules of variable size which may progress to ulceration (Coelho and Coutinho-Abath 1965; Coutinho-Abath and Coelho 1965; Mata *et al.* 1968). With time, metastases appear in the extremities (Coelho and Coutinho-

¹ Present address: Centro de Microscopia Eletrônica, Fundação Oswaldo Cruz (Manguinhos), Caixa Postal 926, 21.040 Rio de Janeiro, Brazil.

² Present address: Centro de Imunologia Parasitária, Fundação Oswaldo Cruz (Manguinhos), Caixa Postal 926, 21.040 Rio de Janeiro, Brazil.

Abath 1965; Coutinho-Abath and Coelho 1965; Mata *et al.* 1968) and visceralization may occur (Mata *et al.* 1968). In contrast, in C57BL/6 and AKR mice (Perez *et al.* 1978, 1979), lesions heal spontaneously.

The apparent lack of acquired resistance to *L. mexicana* in several strains of mice has led some authors to postulate that cellular immune responses which normally control leishmanial infection are defective, perhaps due to the massive invasion of draining lymph nodes by the parasites or to specific suppression by high levels of antigen-antibody complexes (Alexander and Phillips 1978a). Perez *et al.* (1978) have described diminished cellular and humoral immune responses and persistent lesions in BALB/c mice as compared to the C57BL/6 strain, in which lesions heal spontaneously.

In this study the humoral and cellular immune responses of C3H mice infected with *L. mexicana* are correlated with the histopathologic aspects of the infection. A relatively low inoculum (10^5 promastigotes) resulted in moderate long-term infections. Under these experimental conditions, C3H mice developed progressive lesions with concomitant humoral and cellular immune responses to the parasite.

MATERIALS AND METHODS

Mice. Young adult inbred C3H mice, of both sexes, maintained in the Department of Pathology, Federal University of Bahia, were used. Infected animals were sacrificed for examination after 3, 5, and 8 months.

Parasites. *Leishmania mexicana*, "strain 5," supplied by Dr. Z. Brener (Centro de Pesquisas René Rachou, Fiocruz, Belo Horizonte, Brazil), was maintained by serial subcutaneous passage in outbred albino Swiss-Webster mice. To obtain parasites for experimental infections, lesion fragments from chronically infected mice were cultured initially in NNN blood agar with an overlay of Hanks' balanced salt solution (HBSS). When promastigotes appeared, the parasites were subinoculated into LIT

liquid medium modified by Gutteridge *et al.* (1969).

After a 1-week growth, the promastigotes were washed three times with HBSS using centrifugation and counted in a Neubauer hemocytometer. Animals were inoculated subcutaneously in the perinasal region with 10^5 organisms in 0.1 ml.

Intradermal hypersensitivity tests. Delayed-type hypersensitivity response to leishmanial antigens was done according to the method of Robinson and Naysmith (1976). The antigen consisted of heat-killed *L. mexicana* promastigotes suspended in phosphate-buffered saline (PBS) pH 7.2 with 0.4% phenol (Pessoa and Barretto 1948). A volume of 0.03 ml containing 6×10^4 parasites was injected into the dorsal surface of one ear using syringe and 27-gauge 1/2-in. needles. The diluent control was injected in the opposite ear. Reactions were measured as ear thickness (mean of three measurements) with a Starrett micrometer caliper at 48 hr after injection. The histology of the leishmanial antigen and control skin test sites was compared to that obtained in mice sensitized with BCG and tested with PPD (Grimaldi *et al.*, in press).

Indirect immunofluorescence test (IFAT). The test was performed as described by Miles (1972). The antigen consisted of *L. mexicana* promastigotes grown in LIT cultures. Parasites were washed three times in PBS pH 7.2 and the concentration was adjusted so that 5 to 10 parasites were present in each high-power field. After drying, the smears were fixed in acetone and incubated for 45 min with serum dilutions. Each individual serum was tested in serial doubling dilutions from 1:8 to 1:2048 in PBS. After washing, slides were incubated with fluorescein-conjugated rabbit anti-mouse IgG and with goat anti-mouse IgM, diluted 1:20 (Cappel Laboratories, Cochranville, Pa.) for 45 min. After further washing, the smears were mounted in buffered glycerol and examined with a Zeiss fluorescent microscope with a

halogen light source, dark field condenser, FITC interference filter, and OG-515 (1 mm) barrier filter. Immunofluorescence was graded visually on a scale of 1+ to 4+. Titers were expressed as the reciprocal of the highest serum dilution giving 2+ cytoplasmic fluorescence (Preston *et al.* 1972). Pooled normal mouse serum was included in each IFAT and IHA test run and was invariably negative. Pooled serum from chronically infected outbred SW mice was included in each test run as a positive control.

Indirect hemagglutination (IHA). The IHA microtiter procedure of Kagan and Norman (1976) was used. *L. mexicana* antigen was prepared by homogenizing washed promastigotes swelled in distilled water with 0.01 M 2-mercaptoethanol (Cerisola 1974). After centrifugation at 1000g the protein concentration of the supernatant was determined (Lowry *et al.* 1951). The optimal concentration of antigen for the IHA test was 3 µg/ml. For the test, sera were heat inactivated and serially diluted in PBS pH 7.2 with 1% normal rabbit serum (NRS). The titer was designated at the reciprocal of the highest dilution producing a mat of cells covering the bottom of the well. Controls included the diluent, normal mouse serum, immune mouse serum, and both sensitized and nonsensitized tanned cells in 1% NRS.

Pathology. The size and appearance of the leishmanial lesions were evaluated weekly. Lesions were classified according to diameter: large (more than 1 cm); medium (0.6 to 1 cm); small (0.2 to 0.5 cm); minimal (less than 0.2 cm). The animals were also examined for metastases. At sacrifice, the cutaneous lesions were removed and fixed in Bouin's solution. Paraffin sections (5 µm) were made from central and peripheral zones of the lesion and stained with hematoxylin-eosin, Masson's trichrome, and Dominici's stain (Litt modification) (Litt 1963). Histological sections were examined in a blind fashion by two

observers who judged nine features of dermal pathology, scored on a scale of 1+ to (3+) (Table I). Perinasal tissue from uninfected mice was also included in the blind study series.

RESULTS

All animals when sacrificed had histological and immunological evidence of infection (Table I; Figs. 1-11). Although infected simultaneously with the same number of promastigotes, individual mice developed lesions ranging from minimal to large. This size variation of the lesions became apparent by the third month and was maintained throughout the study. Large lesions did not regress with time, but animals with small or minimal lesions at 3 months did not develop large nodules, even after 8 months of infection. Metastases were not observed.

Pathology

A firm, elastic, yellowish-white nodule developed at the site of the parasite inoculation. The covering epidermis was intact but had loss of hair. The cut surface of large, medium, and small lesions was yellowish-white and homogeneous, that of minimal lesions had a whiter more fibrous consistency.

The histopathological findings in the dermis are summarized in Table I. Regardless of the lesion size, the nodule was diffusely infiltrated with histiocytes, lymphocytes, and plasma cells. Neutrophils accompanied the mononuclear infiltrate in 65% of lesions and eosinophils in 45%. In medium to large lesions, the inflammatory infiltrate (Fig. 6) encircled a central area of vacuolated macrophages and nonvacuolated histiocytes (Fig. 5), and was best seen at the periphery of the lesion. *Leishmania mexicana* amastigotes were identified in 50% of the lesions. Larger lesions tended to form histiocyte aggregates while smaller lesions tended to be fibrose. Once formed, the characteristics of

TABLE I
Histopathological Alterations in Cutaneous Lesions Caused by *Leishmania mexicana* in C3H Mice^a

Group and animal	Dermal histopathology											Lesion size
	Histiocytes	Vacuolated macrophages	Macrophages with parasites	Necrosis	Neutrophils	Lymphocytes	Plasma cells	Eosinophils	Fibroblasts with fibrosis			
(I) 3 months												
1	3+	3+	3+	+	2+	2+	2+	+				Me
2	2+	+	+			2+	2+		2+			S
3	2+					2+	2+		2+			S
4	2+					2+	2+		2+			S
(II) 5 months												
1	3+	3+	3+	2+	2+	+						L
2	3+	2+	2+	2+	2+	+						Me
3	2+	+	+		2+	2+		+	2+			Me
4	3+	2+	2+		+	+		+	+			Mn
5	+	+	+		+	+		+	+			Me
6	2+	+	+		2+	2+		+	2+			S
7	2+				2+	2+		+	2+			S
8	+				+	+		+	+			Mn
(III) 8 months												
1	3+				+	2+		+				L
2	3+				+	2+		2+				Mn
3	3+	3+	3+	2+	+	+						L
4	+				+	2+						Mn
5	+				2+	2+		+	2+			Mn
6	3+	+	+		2+	2+		+	2+			S
7	3+	+	+		+	2+			2+			S
8	2+				2+	2+		+	2+			Mn

^a Legend: (+) = slight; (2+) = moderate; (3+) = intense; (L) = large; (Me) = medium; (S) = small; (Mn) = minimal.

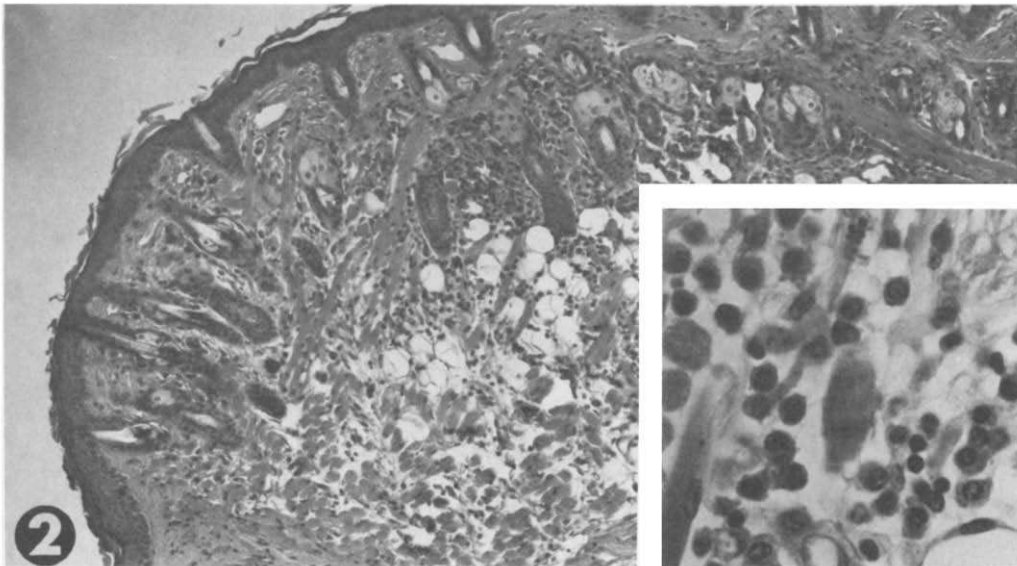
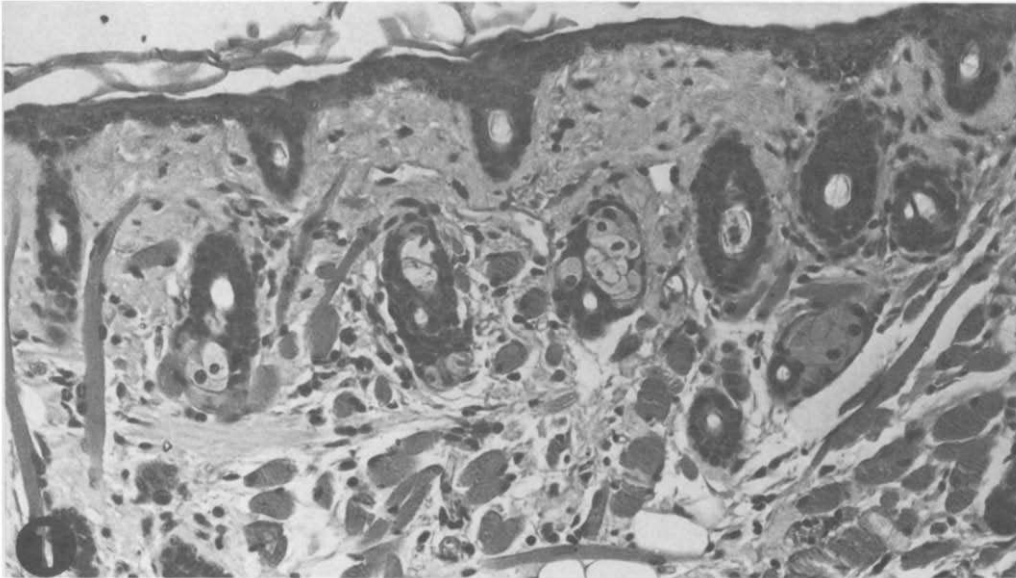


FIG. 1. Histological appearance of normal perinasal skin of C3H mouse (H&E $\times 1000$).

FIG. 2. *Leishmania mexicana*: Minimal lesion, 5 months: Slight diffuse infiltration of mononuclear inflammatory cells in the dermal conjunctive tissue, extending focally to the subcutaneous level (H&E, $\times 400$). Inset: Detail of mononuclear infiltration ($\times 1400$).

the inflammatory infiltrate did not change during the 8 months of observation.

Hypersensitivity Responses

Ear thickness reactions were measured, after 3 months of infection, at 24, 48, 72,

and 96 hr after antigen injection. Ear thickness reached a peak at 48 hr and then remained stable until 96 hr; 48-hr reactions for all animals are shown in Fig. 10. The ear thicknesses of uninfected animals injected with diluent or with *L. mexicana* antigen and infected animals injected with diluent

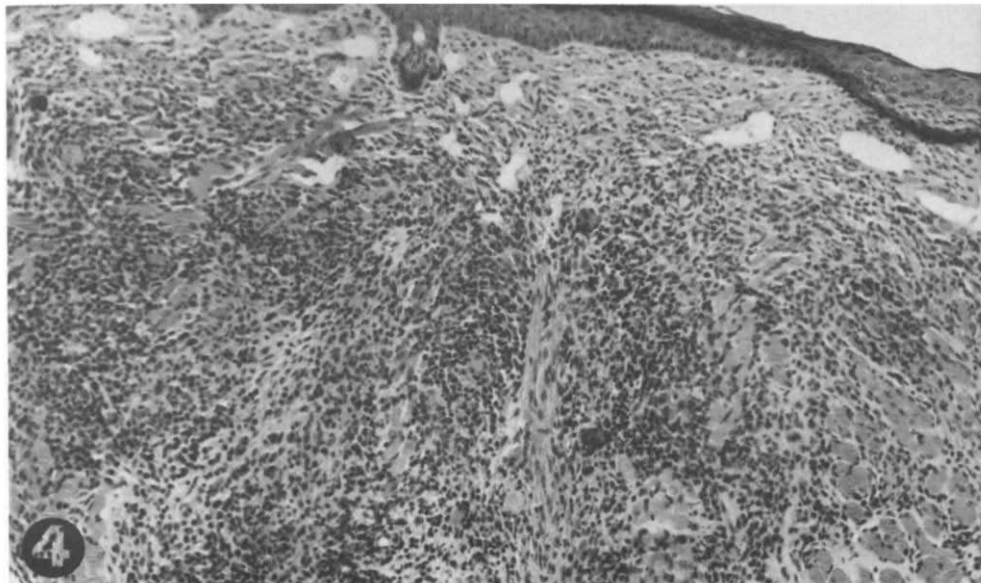
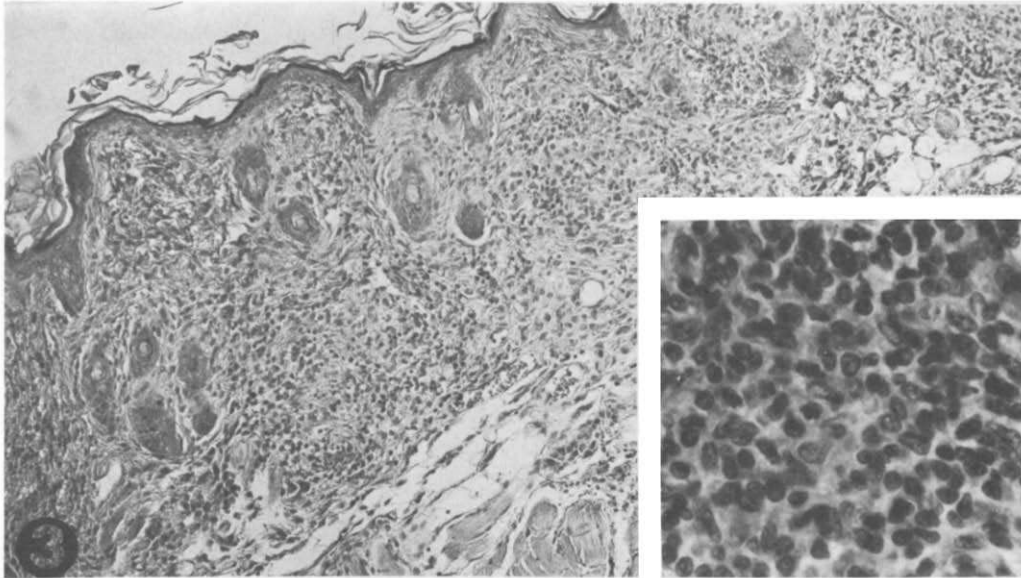


FIG. 3. *Leishmania mexicana*: Minimal lesion, 8 months: Fibrous thickening of the dermal conjunctiva, with moderate diffuse infiltration of mononuclear inflammatory cells. (H&E, $\times 400$). Inset: Detail of mononuclear infiltration ($\times 1400$).

FIG. 4. *Leishmania mexicana*: Small lesion, 5 months: fibrous thickening of the dermal conjunctiva. Intense diffuse infiltration of mononuclear inflammatory cells, with focal areas of clustering (H&E, $\times 500$).

were not significantly different (rank sum test, $P > 0.05$) (Snedecor 1956). Ear thickness of uninjected mice was 0.32 ± 0.01 (SD) mm ($N = 11$). Infected animals injected with *L. mexicana* antigen had ear

thickness responses significantly greater than control animals (rank sum test, $P < 0.01$). In infected mice, the cutaneous response to *L. mexicana* antigen was similar after 3, 5, and 8 months of infection (rank

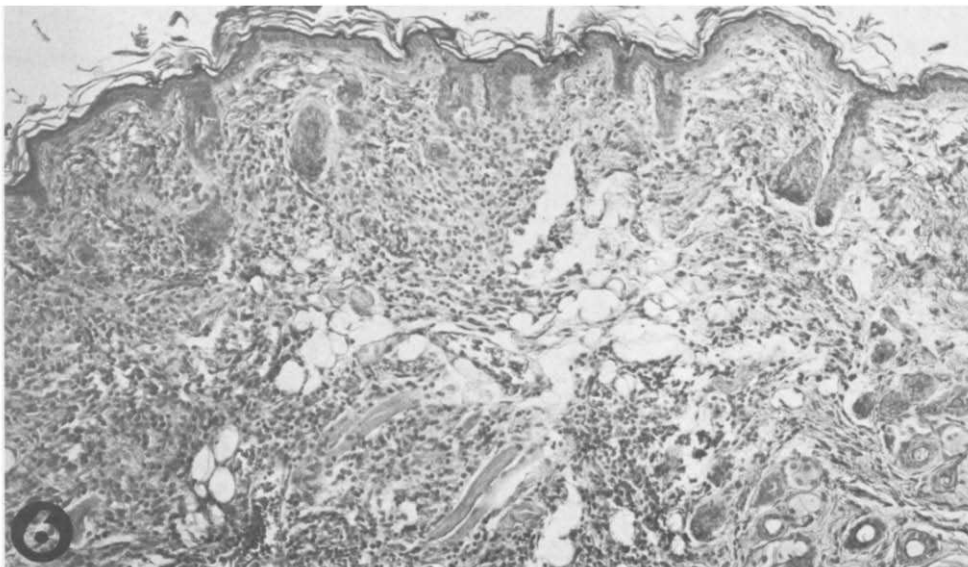
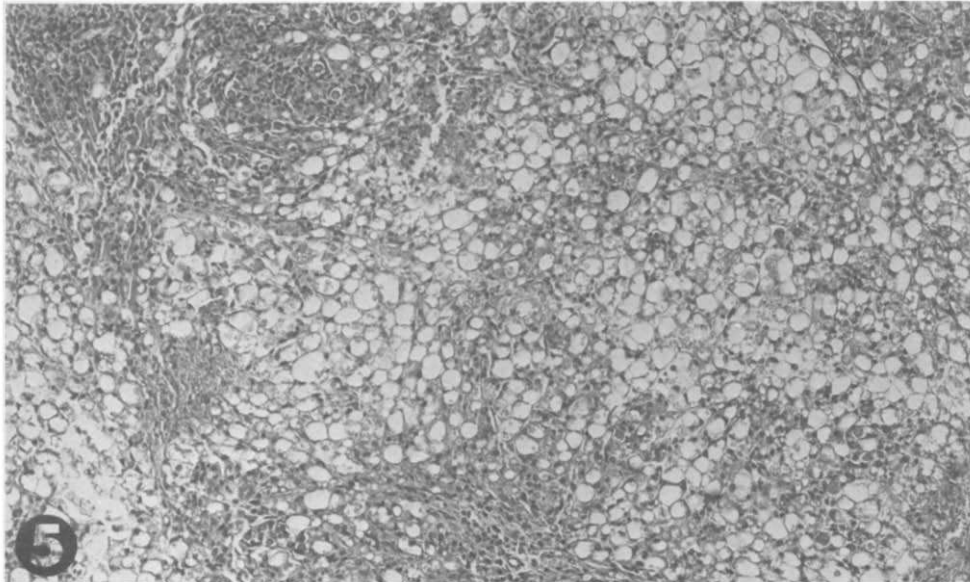


FIG. 5. *Leishmania mexicana*: Medium lesion, 5 months: central area of the lesion, showing dilated monovacuolated macrophages (H&E, $\times 400$).

FIG. 6. *Leishmania mexicana*: Same lesion as Fig. 5: section from the periphery of the lesion, showing a moderate diffuse mononuclear infiltration of the dermis, with focal extensions into the subcutaneous tissue (H&E, $\times 400$).

sum test, $P > 0.05$). The ear thickness did not correlate with size of lesions developed by the individual mice.

Histologically, the skin tests of normal and *L. mexicana*-infected mice injected

with diluent had slight to moderate congestion and edema (36% of cases) and slight to moderate infiltration of neutrophils (42% of cases). Similarly, the skin tests of uninfected animals injected with leishmanial

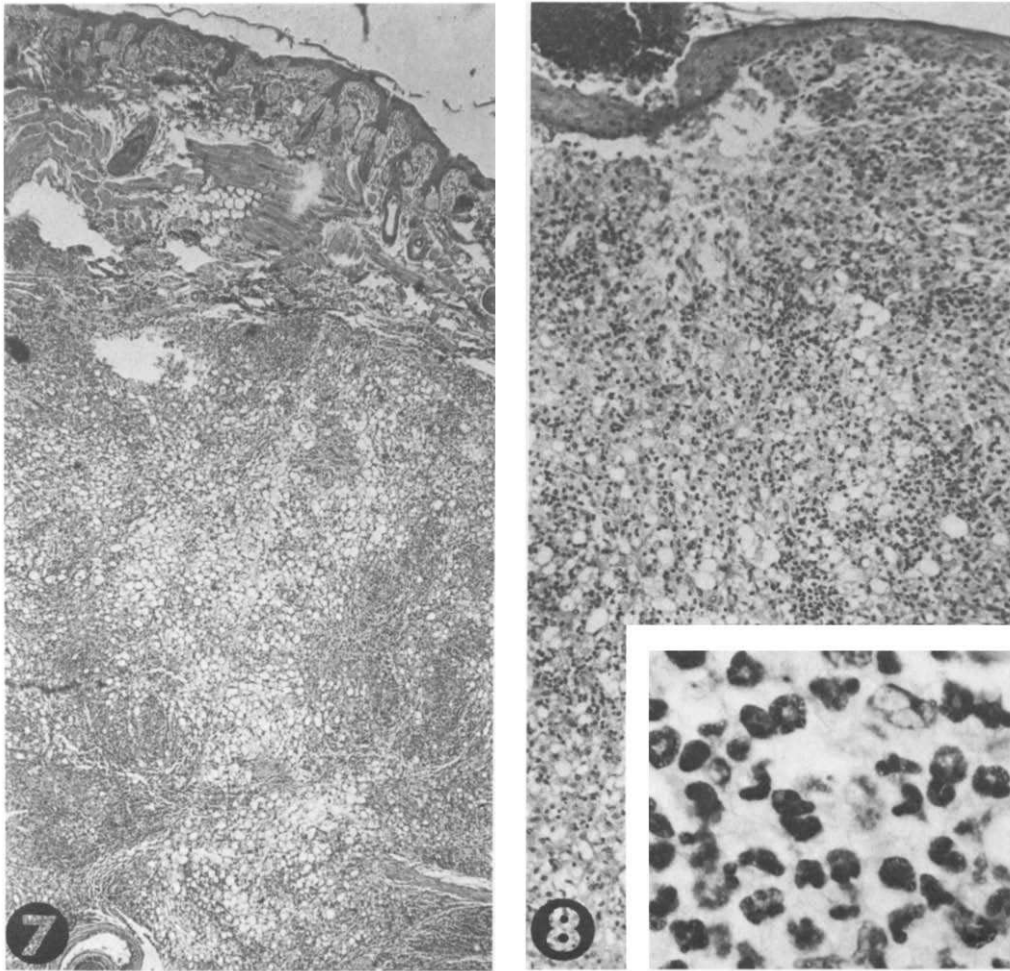


FIG. 7. *Leishmania mexicana*: Large lesion, 8 months: histiocyte aggregate, restricted to and replacing the subcutaneous tissue. Dense areas of "compact" macrophages are visible, interspersed with vacuolated macrophages (H&E, $\times 160$).

FIG. 8. *Leishmania mexicana*: Large lesion, 8 months: histiocyte aggregates extending from the dermal conjunctiva to the deep layers of the skin. Focal clusters of polymorphonuclear neutrophils are present. (H&E, $\times 500$). Inset: Detail of neutrophil infiltration ($\times 1400$).

antigen had slight to moderate congestion and edema (57%) and slight to moderate neutrophil infiltration (57%). In contrast, the skin tests in *L. mexicana*-infected mice injected with leishmanial antigen had slight to moderate infiltration of histiocytes and lymphocytes into the dermal conjunctive tissue. In addition, the leishmanial skin tests of infected animals had a moderate to intense infiltrate of neutrophils (100% of

cases) and moderate to intense congestion and edema (80%), at times with extravasation of erythrocytes (40%). The intensity of the mononuclear infiltrate in the skin test did not appear to be related to either the duration of the infection or to the ear thickness. The histologic characteristics of the leishmanial skin test resembled that of BCG-immunized mice skin-tested with PPD antigen (Grimaldi *et al.*, in press).

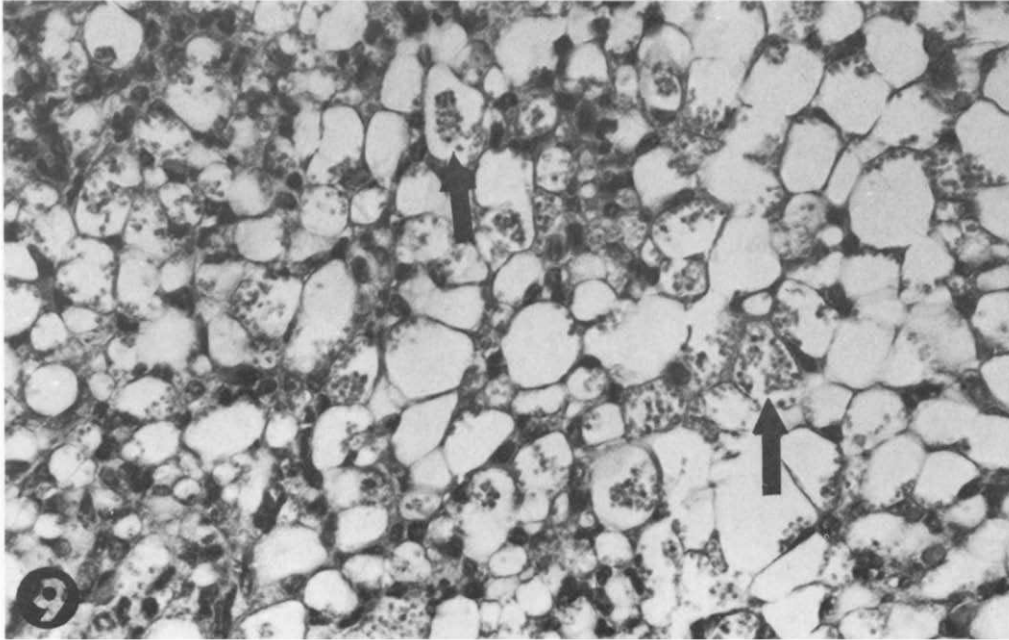


FIG. 9. *Leishmania mexicana*: Large lesion, 8 months: detail of histiocyte aggregate showing dilated monovacuolated macrophages containing amastigotes (arrows) (H&E, $\times 2000$).

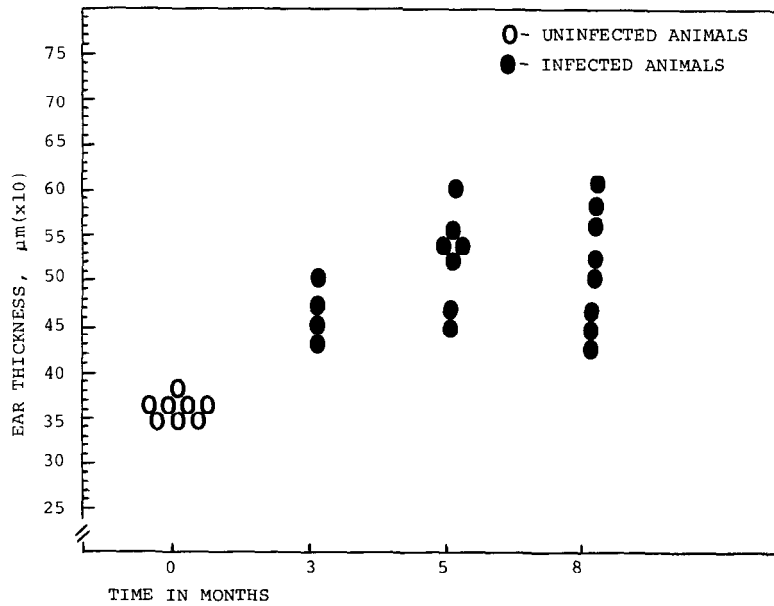


FIG. 10. Intradermal reaction to leishmanial antigen (48 hr) in the ears of C3H mice infected with *Leishmania mexicana*.

Indirect Immunofluorescence

IgG antibodies to *L. mexicana* were found in all infected animals (Fig. 11), in titers varying from 1:16 to 1:1024. IgM antibodies were detected in 90% of infected animals, generally at lower titers than IgG antibodies. IgM and IgG antibody titers did not vary significantly during the infection (rank sum test, $P > 0.05$).

Indirect Hemagglutination

Specific hemagglutinating antibodies were detected in 90% of the infected animals in titers ranging from 1:16 to 1:256. Titers of the three groups did not differ significantly (rank sum test, $P > 0.05$).

DISCUSSION

Leishmania mexicana produced progressive nonhealing lesions in C3H mice, a finding which has been reported for other inbred and outbred strains of mice (Coelho and Coutinho-Abath 1965; Coutinho-Abath and Coelho 1965; Mata *et al.* 1968; Alexander and Phillips 1978a, b; Perez *et al.* 1978,

1979). However, unlike some other mouse strains, neither ulceration nor metastases of the *L. mexicana* lesions were observed in the C3H mouse, even when primary nodules reached large dimensions (1 cm).

The tissue response to *L. mexicana* infection in the C3H mouse also appeared to differ from that of some other hosts. We observed a diffuse infiltrate of lymphocytes, plasma cells, and histiocytes without any evidence of tuberculoid-type granuloma formation. Coutinho-Abath and Coelho (1965) found granulomas with infiltration by lymphocytes, plasma cells, and neutrophils in *L. mexicana*-infected mice and hamsters. Alexander and Phillips (1978a) found almost no lymphocytes in the *L. mexicana* lesions of outbred CFLP and inbred CBA and NIH mice, which also produce nonulcerating, nonhealing lesions. Lainson and Strangeways-Dixon (1964), on the other hand, found areas of intense lymphocyte and plasma cell infiltration in the lesions of naturally infected wild rodents. In the *L. mexicana* lesions of C3H mice, lymphocyte infiltration, although not uni-

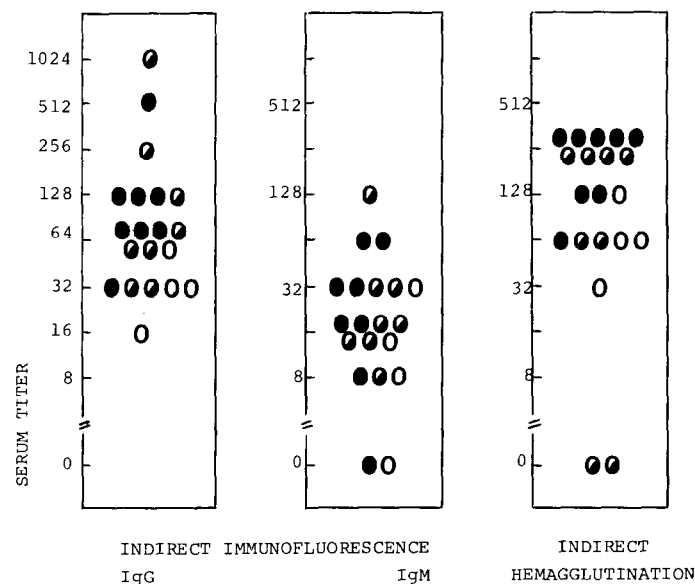


FIG. 11. Antibody responses of C3H mice infected with *Leishmania mexicana*. Infection times: (○) 3 months; (◐) 5 months; (●) 8 months.

formly distributed in the lesions, was present regardless of the lesion size, parasite numbers, or duration of infection. It has been postulated that the mechanism whereby *L. mexicana* evades host defenses is through specific immunosuppression (Alexander and Phillips 1978a). However, the same authors have shown that lymph nodes draining *L. mexicana* lesions in mice have germinal center activation and hyperplasia of pericortical regions, suggestive of induction of both humoral and cellular immune mechanisms. In the spectrum of cutaneous leishmaniasis, delayed-type hypersensitivity reactions are usually absent in the diffuse form and present in the healing and chronic ulcerating forms of the disease (Preston and Dumonde 1976). Interestingly, in C3H mice, as well as in some other strains (Perez *et al.* 1979), the presence of delayed-type hypersensitivity reactions to leishmanial antigens was not accompanied by healing or by ulceration of *L. mexicana* lesions. C3H/He mice, however, are capable of healing *L. tropica* infections, even with infective doses of up to 2×10^7 promastigotes (Handman *et al.* 1979; Behin *et al.* 1979). The ability of different species and perhaps of different isolates of leishmania (Wilson *et al.* 1979) to resist destruction by activated host macrophages (Handman *et al.* 1979; Behin *et al.* 1979) may thus play a decisive role in the outcome of infection.

Comparative study of *L. mexicana* infection in inbred mouse strains shows promise for elucidating the mechanisms of protective immunity in cutaneous leishmaniasis. Lesion histopathology, as well as immunological responses and macrophage function, are important parameters to be investigated in such studies.

ACKNOWLEDGMENTS

The data presented in this paper have been submitted by Gabriel Grimaldi, Jr. as part of a thesis for a Master's Degree in Pathology at the Faculty of Medicine of the Federal University of Bahia, Salvador, Bahia. The authors wish to thank Dr. Sonia G.

Andrade of the Department of Pathology for the helpful advice in the planning and execution of the experiments and in the preparation of the manuscript. We also wish to thank Dr. Aristides Quieroz for participating in the histopathologic evaluation.

REFERENCES

- ALEXANDER, J., AND PHILLIPS, R. S. 1978a. *Leishmania tropica* and *Leishmania mexicana*: Cross-immunity in mice. *Experimental Parasitology* 45, 93–100.
- ALEXANDER, J., AND PHILLIPS, R. S. 1978b. *Leishmania mexicana* and *L. tropica*: Inhibition of growth in mice by concurrent infections of *Trypanosoma brucei*. *Experimental Parasitology* 44, 136–142.
- BEHIN, R., MAUEL, J., AND SORDAT, B. 1979. *Leishmania tropica*: Pathogenicity and in vitro macrophage function in strains of inbred mice. *Experimental Parasitology* 48, 81–91.
- BRADLEY, D. J. 1977. Regulation of *Leishmania* populations within the host. II. Genetic control of acute susceptibility of mice to *Leishmania donovani* infection. *Clinical and Experimental Immunology* 30, 130–140.
- BRADLEY, D. J., AND KIRKLEY, J. 1977. Regulation of *Leishmania* populations within the host. I. The variable course of *Leishmania donovani* infections in mice. *Clinical and Experimental Immunology* 30, 119–129.
- CERISOLA, J. A. 1974. Diagnostico de laboratorio de la enfermedad de Chagas. Reacción de hemaglutinación (RHA). *Anales de la Fundación Laboratorios de Investigaciones Pediátricas (FLIP)*, 42–45.
- COELHO, M. V., AND COUTINHO-ABATH, E. 1965. Experimental cutaneous leishmaniasis. I. Infection of albino mice and syrian hamsters by *Leishmania mexicana*. *Revista do Instituto de Medicina Tropical de São Paulo* 7, 136–144.
- COUTINHO-ABATH, E., AND COELHO, M. V. 1965. Experimental cutaneous leishmaniasis. II. The pathology of leishmaniasis by *Leishmania mexicana*. *Revista do Instituto de Medicina Tropical de São Paulo* 7, 145–155.
- GRIMALDI, G. F., MORIEARTY, P. L., AND HOFF, R. 1980. *Leishmania mexicana* in C3H mice. BCG and Levamisole treatment of established infections. *Clinical and Experimental Immunology*, in press.
- GUTTERIDGE, W. E., KNOWLER, J., AND COOMBS, J. D. 1969. Growth of *Trypanosoma cruzi* in human heart tissue cells and effects of aminonucleoside of Puromycin, Trypacydin and Aminopterin. *Journal of Protozoology* 16, 521–525.
- HANDMAN, E., CEREDIG, R., AND MITCHELL, G. F. 1979. Murine cutaneous leishmaniasis: Disease patterns in intact and nude mice of various genotypes and examination of some differences between nor-

- mal and infected macrophages. *Australian Journal of Experimental Biology and Medical Science* 57, 9-29.
- KAGAN, I. G., AND NORMAN, L. 1976. Serodiagnosis of parasitic diseases. Indirect hemagglutination test. In "Manual of Clinical Immunology" (N. R. Rose and H. Friedman, eds.), pp. 392-394. Amer. Soc. Microbiol., Washington D.C.
- LAINSON, R., AND SHAW, J. J. 1978. Epidemiology and ecology of leishmaniasis in Latin-America. *Nature (London)* 273, 595-600.
- LAINSON, R., AND STRANGWAYS-DIXON, J. 1963. *Leishmania mexicana*: The epidemiology of dermal leishmaniasis in British-Honduras. I. The human disease. *Transactions of the Royal Society of Tropical Medicine and Hygiene* 57, 242-265.
- LAINSON, R., AND STRANGWAYS-DIXON, J. 1964. The epidemiology of dermal leishmaniasis in British-Honduras. II. Reservoir-hosts of *Leishmania mexicana* among the forest rodents. *Transactions of the Royal Society of Tropical Medicine and Hygiene* 58, 136-153.
- LITT, M. 1963. Studies in experimental eosinophilia. V. Eosinophils in lymph nodes of guinea pigs following primary antigenic stimulation. *American Journal of Pathology* 52, 529-550.
- LOWRY, O. H., ROSEBROUGH, N. J., FARR, A. L., AND RANDALL, R. J. 1951. Protein measurement with the folin phenol reagent. *Journal of Biological Chemistry* 193, 265-275.
- MATA, A. D., RUIZ, C. B., GASCA, E. F., AND MORALES, M. C. 1968. Infección experimental con cepas mexicanas del agente causal de la leishmaniasis cutánea. *Salud Publica de Mexico* 10, 159-171.
- MILES, M. A. 1972. *Trypanosoma cruzi*-milk transmission of infection and immunity from mother to young. *Parasitology* 65, 1-9.
- PÉREZ, H., ARREDONDO, B., AND GONZÁLEZ, M. 1978. Comparative study of American cutaneous leishmaniasis and diffuse cutaneous leishmaniasis in two strains of inbred mice. *Infection and Immunity* 22, 301-307.
- PÉREZ, H., LABRADOR, F., AND TORREALBA, J. W. 1979. Variations in the response of five strains of mice to *Leishmania mexicana*. *International Journal for Parasitology* 9, 27-32.
- PESSOA, S. B., AND BARRETTO, M. P. 1948. "Leishmaniose Tegumentar Americana." Ministério da Educação e Saúde, Serviço de Documentação, São Paulo.
- PRESTON, P. M., CARTER, R. L., LEUCHARS, E., DAVIES, A. J. S., AND DUMONDE, D. C. 1972. Experimental cutaneous leishmaniasis. III. Effects of thymectomy on the course of infection of CBA mice with *Leishmania tropica*. *Clinical and Experimental Immunology* 10, 337-357.
- PRESTON, P. M., AND DUMONDE, D. C. 1976. Immunology of clinical and experimental leishmaniasis. In "Immunology of Parasitic Infections" (S. Cohen and E. Sadun, eds.), pp. 167-202. Blackwell, Oxford.
- ROBINSON, J. H., AND NAYSMITH, J. D. 1976. A comparison of four methods for measuring cutaneous delayed-type hypersensitivity reactions to protein antigens in the mouse. *Scandinavian Journal of Immunology* 5, 299-304.
- SNEDECOR, G. W. 1956. "Statistical Methods," 5th ed. Iowa State Univ. Press, Ames, Iowa.
- WILSON, H. R., DIECKMANN, B. S., AND CHILDS, G. E. 1979. *Leishmania braziliensis* and *Leishmania mexicana*: Experimental cutaneous infections in golden hamsters. *Experimental Parasitology* 47, 270-283.