

## Corporoplasty Using Bovine Pericardium Grafts in Complex Penile Prosthesis Implantation Surgery

Eduardo J. A. Lopes, Andre Y. Kuwano, Andreia N. Guimaraes, Jesuino P. Flores, Modesto A. O. Jacobino

*Section of Urology, School of Medicine, Federal University of Bahia, Salvador, Bahia, Brazil*

---

### ABSTRACT

*Purpose:* This paper is the first, to our knowledge, to propose the use of a bovine pericardium graft in corporoplasty for penile prosthesis implantation. The advantages of bovine pericardium graft have been demonstrated by its use in cardiac surgery, including low cost, biocompatibility, impermeability, resistance to dilatation, flexibility, low likelihood of retraction, absence of antigenic reaction and natural absorption of the tissue. In this paper, we propose the use of this heterologous material graft in corporoplasty for penile prosthesis implantation.

*Materials and Methods:* Five patients with a history of erosion, infection and fibrosis, mean time of follow-up 32 months (range 9-48 months). Bovine pericardium was used to cover large areas of implanted penile prostheses when use of the tunica albuginea was unfeasible.

*Results:* The surgical procedure resulted in no complications in all patients.

*Conclusions:* Bovine pericardium may substitute synthetic and autologous material with the additional advantages of lower cost and greater availability.

**Key words:** *penile prosthesis; infection; penile fibrosis; graft; bovine pericardium*

**Int Braz J Urol.** 2009; 35: 49-55

---

### INTRODUCTION

Many materials, both natural and synthetic, have been used to substitute part of the tunica albuginea during corporoplasty and also as material for grafts in penile prosthesis implantation (1). Various series have reported the use of synthetic products such as Gore-Tex, Marlex, Dacron and Silicone (2-4). However, the complication rate following penile grafts of these synthetic materials is high and includes high infection rates, greater risk of fibrosis and absence of elasticity (2-4). Biological materials such as dermis, vein, fascia temporalis, tunica vaginalis and even part of the albuginea of the corpora cavernosa have been used to recompose defects in the penis (5-

12). Although they are not immunogenic and have a lower probability of rejection, biological materials are far from being the ideal substitutes for the tunica albuginea, in most cases due to their low tensile strength. The need for an additional incision increases the duration of surgery, the cost and the possibility of complications in patients who are already debilitated due to the presence of degenerative diseases (6-8,12). Disadvantages of the use of cadaveric pericardium include the high cost and poor availability of this material (9-11). This paper reports the first use of bovine pericardium grafts in penile prosthesis implantation in a small series of cases of extreme complexity in which there was insufficient space for implantation of the prosthesis due to intense fibrosis (13-16).

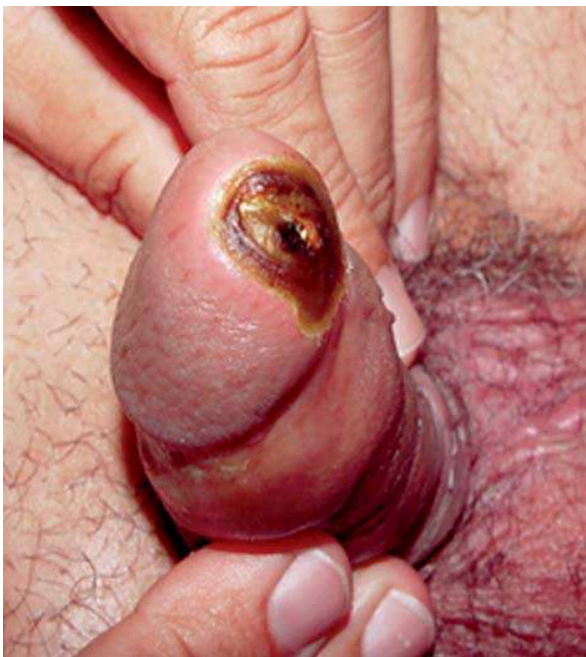## MATERIAL AND METHODS

Five patients with a previous medical history of erosion, infection and fibrosis were submitted to implantation of penile prosthesis lined by bovine pericardium. The opening space for implantation by simple cavernotomy and corporotomy was not enough to insert the thinner prosthesis.

The mean age of patients was 38.4 years. The mean number of previous surgeries to which these patients had been submitted was 1.8 and the mean time of follow-up was 32 months (range 9-48 months).

Patient #1 presented one of the cylinders of the prosthesis extruding from the urethra (Figure-1). During surgery for reimplantation, the existence of a single space was found in the corpora cavernosa. In view of the infection and the urethral lesion, a conservative treatment was chosen. Reimplantation of a single unit was performed 60 days after resolution of the infectious process.

Patients #2, #3 and #5 had fibrosis of corpus cavernosum after several events of priapism caused by sickle-cell anemia. All of the patients had priapism



**Figure 1** – Prosthesis extruding from the urethra.

episodes during more than 72 hours, without receiving appropriate medical assistance. Patient #5 also had type 1 diabetes mellitus.

Patient #4 had prostate cancer and was treated by radical prostatectomy; however, he developed erectile dysfunction and underwent an implantation of flexible penile prosthesis. An infection developed, and the patient had the prosthesis removed. Six months later, a new prosthetic implant was performed. Due to the intense fibrosis and the small space within the corpus cavernosum, the pair of implanted prosthesis was lined with 10 cm segment of bovine pericardium sutured to the albuginea.

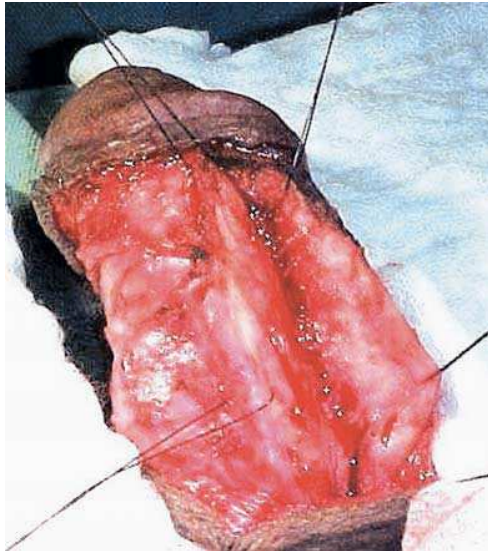
All five patients underwent surgery, which was performed by the same surgeon between January 2003 and December 2006.

## SURGICAL TECHNIQUE

All patients started to receive prophylactic antibiotic therapy two hours prior to surgery and maintained for 7 days following the surgical procedure. The drug of choice was ceftriaxone. Gentamicin diluted in 0.9% saline solution was used to repeatedly clean the surgical field. Spinal (epidural) anesthesia was used. Malleable prostheses were implanted in all cases. The incision adopted was penoscrotal in 4 cases and circular subcoronal degloving incision in one case.

In case #1, the tunica albuginea was thickened and the spongy tissue had been replaced by fibrosis (Figure-2). Only a single space was found; hence, it was only possible to implant one single unit of the penile prosthesis. Since there was small space and the albuginea could not be used to cover the prosthesis, a 10 cm segment of thin bovine pericardium was sutured to the remaining tunica albuginea using continuous polyglactic acid 2-0 sutures.

Due to the intense fibrosis in the corpora cavernosa of patients #2, #3, #4 and #5, it was not practical to implant even the thinnest penile prosthesis available. In these cases, 8-10 cm segments of bovine pericardium were used to complement the tunica albuginea lining the cylinders. Medium-thick bovine pericardium grafts were fixed to the albuginea using continuous polyglactic acid 2-0 sutures (Figure-3).



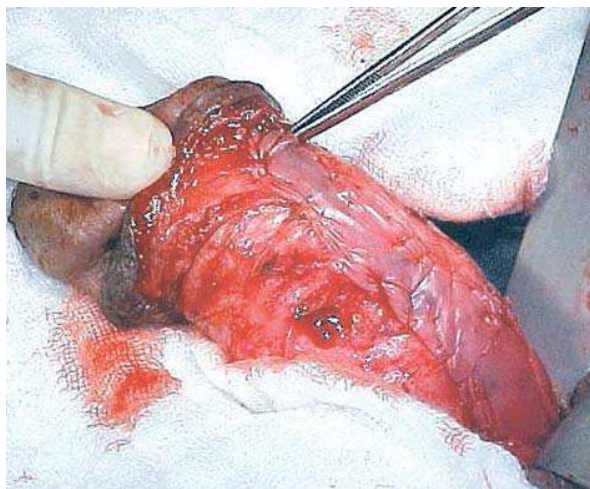**Figure 2** – *Fibrous corpora cavernosa.*

In all 4 cases, the two cylinders of the penile prosthesis were successfully implanted.

The patients were advised to wait at least 8 weeks after prosthesis implantation and albuginea reconstruction before having sexual intercourse.

## RESULTS

There were no complications observed in the immediate postoperative period. After 8 weeks, all



**Figure 3** – *Bovine pericardium lining the prosthesis.*

patients maintained sexual intercourse. None of the patients complained of pain or difficulty to penetrate the vagina of the partner. The average follow-up was 32 months (ranging from 9 to 48 months). All patients were satisfied with the results.

## COMMENT

Extrusion of the penile prosthesis through the tunica albuginea is an uncommon complication following surgical implantation of a penile prosthesis when either synthetic or natural materials are used for reconstruction. Removal of the prosthesis due to infection is one of the major complications of penile prosthesis implantation (Figure-1). Rescue reimplantation procedures are considered extreme measures and have been defended in few reported series (17). Late reimplantation may constitute a complex surgical procedure when the spongy tissue of the corpora cavernosa has been overtaken by fibrosis.

Patients with sickle-cell anemia are relatively common in this geographical region, in which 80% of the population is of African descent. Many of these patients develop stuttering priapism, which is treated with topical therapies. The formation of fibrosis inside the corpora cavernosa makes implantation of even the thinnest prosthesis impracticable without the use of complementary grafts sutured to the tunica albuginea, covering the prosthesis.

Here, for the first time, to our knowledge, we report the use of bovine pericardium to cover large areas of implanted penile prostheses when use of the tunica albuginea is unfeasible (13-16). Although bovine pericardium is a heterologous material, it has been used in heart valve prostheses and vascular grafts for more than 18 years with exceptional results and no rejection or retraction (18). It has been extensively used in the treatment of urological pathologies such as congenital penile curvature and Peyronie's disease (19-22). Moreover, its biocompatibility and resistance have previously been tested in organs in which the circulatory and functional dynamics demand good tensile strength. Its use eliminates the need for a second incision, thereby reducing the time of surgery, risks and the cost for the patient.



Bovine pericardium is an inert material with a low probability of retraction. It has a lower cost than cadaveric pericardium, being, therefore, accessible to any hospital unit. It is available in segments measuring 4.0 x 5.5 cm, 7.6 x 11 cm and 10 x 12.5 cm, and in three different thicknesses (thin, medium and thick) at a cost of 60-90 dollars. It is an heterologous material treated with glutaraldehyde and has no antigenic reaction. It is conserved in a solution of formaldehyde or glycerin and packaged in sterile containers. It is flexible, impermeable and resistant to sutures. Moreover, it does not tear when the suture needle is inserted and is resistant to the traction necessary for a good suture. It is very resistant to tension and may be used to cover large defects without bulging. Bovine pericardium grafts are not subject to rejection, and provoke only a mild inflammatory reaction, if any. It also serves as a framework for the growth of the tunica albuginea along its extension. The remodeling process is long and may take several months.

## CONCLUSIONS

Despite the small number of patients, our results with the use of bovine pericardium as a substitute for the tunica albuginea were optimal. Bovine pericardium is inexpensive, widely available, impermeable, resistant and flexible. Moreover, it has a low probability of retraction, no antigenic reaction and is easily incorporated into the structure of the tissue. Bovine pericardium may substitute synthetic and autologous material with the further advantages of lower cost and greater availability. The processes of sterilization and storage are simple and permit its conservation for long periods of time with no damage to its properties. These advantages make bovine pericardium an accessible material for any patient who requires penile prosthesis implantation in situations of greater complexity.

## CONFLICT OF INTEREST

None declared.

## REFERENCES

1. Fishman IJ: Corporeal reconstruction procedures for complicated penile implants. *Urol Clin North Am.* 1989; 16: 73-90.
2. Smith CP, Kraus SR, Boone TB: Management of impending penile prosthesis erosion with a polytetrafluoroethylene distal wind sock graft. *J Urol.* 1998; 160: 2037-40.
3. Blumenfrucht M, Bhattacharya S, Brunner R, Wise GJ: Penile corporoplasty with polytetrafluoroethylene (PTFE) grafts. *Urology.* 1983; 22: 46-8.
4. Herschorn S, Ordorica RC: Penile prosthesis insertion with corporeal reconstruction with synthetic vascular graft material. *J Urol.* 1995; 154: 80-4.
5. Melman A, Holland TF: Evaluation of the dermal graft inlay technique for the surgical treatment of Peyronie's disease. *J Urol.* 1978; 120: 421-2.
6. Kadioglu A, Tefekli A, Usta M, Demirel S, Tellaloglu S: Surgical treatment of Peyronie's disease with incision and venous patch technique. *Int J Impot Res.* 1999; 11: 75-81.
7. Burnett AL: Fascia lata in penile reconstructive surgery: a reappraisal of the fascia lata graft. *Plast Reconstr Surg.* 1997; 99: 1061-7.
8. Alter GJ, Greisman J, Werthman PE, Seid AS, Joseph BJ: Use of a prefabricated tunica vaginalis fascia flap to reconstruct the tunica albuginea after recurrent penile prosthesis extrusion. *J Urol.* 1998; 159: 128-32.
9. Landman J, Bar-Chama N: Initial experience with processed human cadaveric allograft skin for reconstruction of the corpus cavernosum in repair of distal extrusion of a penile prosthesis. *Urology.* 1999; 53: 1222-4.
10. Hellstrom WJ, Reddy S: Application of pericardial graft in the surgical management of Peyronie's disease. *J Urol.* 2000; 163: 1445-7.
11. Leungwattanakij S, Bivalacqua TJ, Reddy S, Hellstrom WJ: Long-term follow-up on use of pericardial graft in the surgical management of Peyronie's disease. *Int J Impot Res.* 2001; 13: 183-6.
12. Teloken C, Grazziotin T, Rhoden E, Da Ros C, Fornari A, Soares FC, et al.: Penile straightening with crural graft of the corpus cavernosum. *J Urol.* 2000; 164: 107-8.
13. Lopes EJ, Oliveira VS, Lacerda S, Jacobino M: Use of bovine pericardium in penile prosthesis reimplantation. *Official Bulletin of the Brazilian Association for Sexual Inadequacy (ABEIS).* 2003; vol. VII, p. 6-6. [in Portuguese]

14. Lopes EJ, Oliveira VS, Lacerda S, Jacobino M: Penile prosthesis replantation by using bovine pericardium. *Int Braz J Urol.* 2005; 29 (Suppl.): p. 239. (Abst P-030). [in Portuguese]
15. Lopes EJ, Santos TC, Santos DSN, Carrera H: Penile prosthesis implation in neo penis. *Int Braz J Urol.* 2005; 30 (Suppl.): p. 89. (Abst PO-55). [in Portuguese]
16. Lopes EJ, Santos TC, Jacobino M: Bovine pericardium in penile prosthesis reimplantation. *Int Braz J Urol.* 2007; 33: 74-6.
17. Mulcahy JJ, Brant MD, Ludlow JK: Management of infected penile implants. *Tech Urol.* 1995; 1: 115-9.
18. Pomerantzeff PM, Zerbini EJ, Verginelli G, Jatene AD: Valve replacement in the Heart Institute, University of Sao Paulo, Brazil. *Ann Thorac Surg.* 1989; 48 (Suppl. 3): S41-4.
19. Lopes EJ, Oliveira VS, Lacerda S, Jacobino M, Lima DMO: Congenital penile curvature. *Int Braz J Urol.* 2005; 29 (Suppl.): p. 243. (Abst P-045). [in Portuguese]
20. Lopes EJ, Santos TC, Flores JP, Santos DSN: Correction of penile curvature using bovine pericardium. *Int Braz J Urol.* 2005; 30 (Suppl. ): p. 91. (Abst PO-62). [in Portuguese]
21. Lopes EJ, Santos TC, Flores JP, Jacobino M, Carrera H: Peyronie's disease. Elongation of short side with interposition of bovine pericardium. *Int Braz J Urol.* 2005; 30 (Suppl.): p. 63. (Abst TL-275). [in Portuguese]
22. Egydio PH, Lucon AM, Arap S: Treatment of Peyronie's disease by incomplete circumferential incision of the tunica albuginea and plaque with bovine pericardium graft. *Urology.* 2002; 59: 570-4.

---

*Accepted after revision:  
November 10, 2008*

---

**Correspondence address:**

Dr. Eduardo J. A. Lopes  
Rua Altino Seberto de Barros, 241/405  
Salvador, BA, 41850-010, Brazil  
Fax: + 55 71 3351-7424  
E-mail: ejalopes@oi.com.br

## EDITORIAL COMMENT

Burnett and Palese in 2001 (1) first described the use of cadaveric human pericardium graft in complex penile prosthesis surgery. Hellstrom and Reddy (2) described the application of cadaveric human pericardium for tunica albuginea expansion to correct penile curvature associated or not with penile prosthesis implantation and no postoperative evidence of tissue rejection or infection was observed.

Egydio and co-workers (3-5) used the cadaveric bovine pericardium graft applying geometrical principles for the precise placement of tunica incision aiming to expand the cavernous space to allow the penile prosthesis implantation for maximum penile length and girth gain, limited by the length of the dissected neurovascular bundle.

The authors in the present study in fact corroborate with the use of cadaveric bovine pericardium, as a graft, to expand the cavernous space, even in cases associated with cavernous tissue fibrosis.

## REFERENCES

1. Palese MA, Burnett AL: Corporoplasty using pericardium allograft (tutoplast) with complex penile prosthesis surgery. *Urology.* 2001; 58: 1049-52.
2. Hellstrom WJ, Reddy S: Application of pericardial graft in the surgical management of Peyronie's disease. *J Urol.* 2000; 163: 1445-7.
3. Egydio PH, Lucon AM, Arap S: A single relaxing incision to correct different types of penile curvature:

- surgical technique based on geometrical principles. BJU Int. 2004; 94: 1147-57.
4. Egydio PH: Surgical treatment of Peyronie's disease: choosing the best approach to improve patient satisfaction. Asian J Androl. 2008; 10: 158-66.
  5. Egydio PH, Perovic SV, Sansalone S: Surgical treatment of severe Peyronie's disease for maximum penile length and girth gain. J Urol. 2008; 179: 256(Suppl), Abst #733.

**Dr. Paulo H. Egydio**

*Center for Peyronie's Disease*

*São Paulo, SP, Brazil*

*E-mail: phegydio@peyronie.com.br*

## EDITORIAL COMMENT

This is a very interesting paper of heterologous substitution with bovine pericardium for extreme fibrosis and defects of the corporal bodies. Revision-surgery of penile prosthesis, although rather rare, is difficult and challenging. Homologous materials (vein grafts, tunica vaginalis, dermal grafts) are a possibility but an additional operation field is needed. These grafts are routinely used in corporoplasty for Peyronie's disease but are not used in revision-surgery for the covering of a penile prosthesis (1). I personally consider synthetic products such as Gore-Tex and Dacron as obsolete in penile prosthesis surgery due to

the risk of damaging the prosthesis caused by friction with the foreign material. This paper has splendid results but the report only concerns a limited group of patients with median-term follow-up. Larger groups of patients with longer follow-up are needed before considering this treatment as a standard treatment for this difficult type of patients.

## REFERENCE

1. Backhaus BO, Muller SC, Albers P: Corporoplasty for advanced Peyronie's disease using venous and/or dermis patch grafting: new surgical technique and long-term patient satisfaction. J Urol. 2003; 169: 981-4.

**Dr. Nicolaas C. Lumen**

*Department of Urology*

*Ghent University Hospital*

*Ghent, Belgium*

*E-mail: lumennicolaas@hotmail.com*

## REPLY BY THE AUTHORS

The present paper was not on the use of small grafts implantation for rectifying curved penile as in Peyronie's disease, associated or not with penile prosthesis implantation. We presented the partial substitution of tunica albuginea with bovine pericardium for harvesting the implanted prosthesis in cases

of extreme fibrosis and defects of corpora cavernosa (1-3). We performed the same procedure as other authors using different materials (4-7), however, we used bovine pericardium by the first time (1,2). For clarification, pioneering studies have been presented at various congresses (1,2), previously to the cited

publication in 2004 by Dr. Egydio (8), which dealt with penile curvature and not with fibrosis and corpora cavernosa defects. Also, our material was not human cadaveric pericardium as used by Palese and Burnett (7), but bovine pericardium (heterologous material). This graft is routinely used in corporoplasty for Peyronie's disease but is not used in revision-surgery for covering penile prostheses (9).

In 2007, we published the report of the first patient operated on 2000 (1). In the present paper published here, we present our small series of five patients. We agree with Dr. Lumen that it is necessary to include more patients and long-term follow-up for considering this kind of treatment as the gold standard for cases of extreme complexity.

#### REFERENCES

1. Lopes EJ, Oliveira VS, Lacerda S, Jacobino M: Use of bovine pericardium in penile prosthesis reimplantation. Official Bulletin of the Brazilian Association for Sexual Inadequacy (ABEIS). 2003; 7: p. 6-6. [in Portuguese]
2. Lopes EJ, Flores JP, Jacobino M: Reimplantation of penile prosthesis using bovine pericardium. Int Braz J Urol (Suppl.). 2003; 29: p. 33. [in Portuguese]
3. Lopes EJ, Santos T, Jacobino M: Bovine pericardium in penile prosthesis reimplantation. International Braz J Urol, 2007; 33: 74-76.
4. Backhaus BO, Muller SC, Albers P: Corporoplasty for advanced Peyronie's disease using venous and/or dermis patch grafting: new surgical technique and long-term patient satisfaction. J Urol. 2003; 169: 981-4.
5. Palese MA, Burnett AL: Corporoplasty using pericardium allograft (tutoplast) with complex penile prosthesis surgery. Urology. 2001; 58: 1049-52.
6. Hellstrom WJ, Reddy S: Application of pericardial graft in the surgical management of Peyronie's disease. J Urol. 2000; 163: 1445-7.
7. Palese MA, Burnett AL: Corporoplasty using pericardium allograft (tutoplast) with complex penile prosthesis surgery. Urology. 2001; 58: 1049-52.
8. Egydio PH, Lucon AM, Arap S: A single relaxing incision to correct different types of penile curvature: surgical technique based on geometrical principles. BJU Int. 2004; 94: 1147-57.
9. Backhaus BO, Muller SC, Albers P: Corporoplasty for advanced Peyronie's disease using venous and/or dermis patch grafting: new surgical technique and long-term patient satisfaction. J Urol. 2003; 169: 981-4.

*The Authors*