

# Phototherapy Improves Healing of Cutaneous Wounds in Nourished and Undernourished Wistar Rats

Antonio Luiz Barbosa PINHEIRO<sup>1,2</sup>  
Gyselle Cynthia Silva MEIRELES<sup>1</sup>  
Alessandro Leonardo de Barros VIEIRA<sup>1</sup>  
Darcy ALMEIDA<sup>1</sup>  
Carolina Montagn CARVALHO<sup>1</sup>  
Jean Nunes dos SANTOS<sup>2</sup>

<sup>1</sup>Laser Center, School of Dentistry, Federal University of Bahia, Salvador, BA, Brazil

<sup>2</sup>Department of Propedeutics and Integrated Clinics, Federal University of Bahia, Salvador, BA, Brazil

A wound represents the interruption of the continuity of tissue that is followed by damage or cellular death. Wound healing occurs due to a competitive mechanism between the synthesis and lysis of collagen. Any factor that increases collagen lysis or reduces its synthesis may result in changes in the healing process, i.e., nutritional deficiencies. Phototherapies have been suggested as an effective method to improve wound healing. This study evaluated, histologically, the differences in the healing of cutaneous wounds in nourished and undernourished rats following laser therapy or illumination by polarized light. Fifty nourished or undernourished Wistar rats had a standardized wound created on the dorsum and were divided into 6 subgroups: Group 1 – Control (Standard diet; n=5); Group 2 – Control (DBR; n=5); Group 3 – Standard diet + laser therapy ( $\lambda 635\text{nm}$ ;  $20\text{J}/\text{cm}^2$ , n=5; or  $40\text{J}/\text{cm}^2$ , n=5); Group 4 – Standard diet + Bioptron<sup>®</sup> ( $\lambda 400\text{-}2000\text{nm}$ ;  $20\text{J}/\text{cm}^2$ , n=5; or  $40\text{J}/\text{cm}^2$ , n=5); Group 5 – DBR + laser therapy ( $\lambda 635\text{nm}$ ;  $20\text{J}/\text{cm}^2$ , n=5; or  $40\text{J}/\text{cm}^2$ , n=5); Group 6 – DBR + Bioptron<sup>®</sup> ( $\lambda 400\text{-}2000\text{nm}$ ;  $20\text{J}/\text{cm}^2$ , n=5; or  $40\text{J}/\text{cm}^2$ , n=5). The first application of the treatment was carried out immediately after surgery and repeated every 24 h during 7 days. Specimens were routinely processed (wax, cut and stained with H&E and Picrosirius stain) and analyzed under light microscopy. Analysis included re-epithelization, inflammatory infiltrate, and fibroblastic proliferation. Picrosirius stained slides were used to perform descriptive analysis of the collagen fibers. The results showed the best results for nourished and undernourished groups treated with polarized light at a dose of  $20\text{J}/\text{cm}^2$  and the undernourished groups irradiated with the laser light. It is concluded that the nutritional status influenced the progression of the healing process as well as the quality of the healed tissue and that the use of both modalities of phototherapy resulted in a positive biomodulatory effect in both nourished and undernourished subjects. The effect of the polarized light was more evident in nourished subjects and laser therapy more effective in the treatment of undernourished subjects, in both cases with a dose of  $20\text{J}/\text{cm}^2$ .

Key Words: LLLT, cicatrization, diet.

## INTRODUCTION

A wound represents the anatomical or functional interruption of the continuity of tissue that is followed by damage or cellular death. Wound healing occurs due to a competitive mechanism between the synthesis and lysis of collagen. Any factor that increases the lysis or reduces the synthesis of collagen may result in changes in the healing process (1).

The factors that affect healing may be divided

into systemic or local, such as factors that influence the inflammatory response. Nutritional deficiencies have a great effect on wound healing, changing tissue regeneration, inflammatory reaction and immunological function interfering at any point of the healing process. It has been shown that delay of healing may occur in subjects with deficiency of any essential nutrient; although, this situation is reverted to normality by the introduction of a diet with appropriate levels of nutrients.

Correspondence: Prof. Antonio Luiz Barbosa Pinheiro, Av. Araújo Pinho, 62, Canela, 40110-150 Salvador, BA, Brasil. Tel: +55-71-336-5776 Ramal 233; Fax: +55-71-336-5776 Ramal 233. e-mail: albp@ufba.br

The incessant search for methods to minimize pain, to minimize or quicken the inflammatory response and to stimulate cell function and proliferation without harming the tissues has led to the use of light sources.

Laser therapy is used in many biomedical sciences to promote tissue regeneration and has been shown to possess advantages, such as the control of pain, stimulation of the healing process, anti-inflammatory action, increase of collagen production, fibroblastic proliferation, and increase of local micro-vascularization (2).

Another treatment option with light is the use of polarized light sources, which use wavelengths similar to that produced by sunlight. These light sources are not considered to be a "cure", rather they trigger or regulate biological processes helping healing (3).

The present investigation evaluated histologically the differences in the healing of cutaneous wounds in nourished and undernourished rats following laser therapy or illumination by polarized light.

## MATERIAL AND METHODS

Fifty male and female Wistar rats (about 21 days old) were divided into 2 main groups: 1) animals (nourished) fed a standard pellet laboratory diet (Labina®, Purina Nutrimentos, São Paulo, SP) and 2) animals (undernourished) fed a Northeastern Brazilian basic diet (DBR - Department of Nutrition of UFPE) during 30 days in order to induce undernourishment. The procedures for making DBR were carried out at the Laboratory of Experimental Nutrition of the Department of Nutrition of the Federal University of Pernambuco (*Phaseolus vulgaris* = 37.1g%; salted meat and dried meat = 13.9g%; *Iponaea potatoes* = 32.0g%; *Manihot esculenta* = 67.4g%; proteins = 7.88g%; carbohydrates = 69.96g%; fat = 0.60g%; ash = 1.27g%; fibers = 7.0g%).

The surgical procedures were carried out at the Laboratory of Animal Experimentation of the School of Dentistry of the Federal University of Bahia. The animals, about two months old, were submitted to intraperitoneal general anesthesia (0.1ml/1000g Zoletil® 50; Virbac), had their back shaven and a standardized excisional wound measuring 1 x 1 cm was created, without suturing. The wounds were either irradiated with laser light (Kondortech, São Carlos, SP, Brazil)

( $\lambda$ 635nm) or were illuminated with a polarized light source ( $\lambda$ 400-2000nm; Biopton®, Wollerau, Switzerland), both with doses of 20J/cm<sup>2</sup> or 40J/cm<sup>2</sup>. Illumination was carried out using a specially devised guide to obtain a better concentration of the Biopton® light on the area to be treated. The focal distance was kept at 10cm. The animals were divided into six groups: Group 1 – Control (standard diet; n=5); Group 2 – Control (DBR; n=5); Group 3 – Standard diet + laser therapy ( $\lambda$ 635nm, 40mW; 20J/cm<sup>2</sup>, n=5; or 40J/cm<sup>2</sup>, n=5); Group 4 – Standard diet + Biopton® ( $\lambda$ 400-2000nm, 40mW; 20J/cm<sup>2</sup>, n=5; or 40 J/cm<sup>2</sup>, n=5); Group 5 – DBR + laser therapy ( $\lambda$ 635nm; 20J/cm<sup>2</sup>, n=5; or 40J/cm<sup>2</sup>, n=5); Group 6 – DBR + Biopton® ( $\lambda$ 400-2000nm; 20J/cm<sup>2</sup>, n=5; or 40 J/cm<sup>2</sup>, n=5). For all the experimental groups, the first application of the treatment was carried out immediately after the surgical procedure, and repeated every 24 h during the experimental period of 7 days. The animals were sacrificed on the 8th postoperative day. Specimens were taken and routinely processed (wax, cut and stained with H&E and Picosirius stains) and analyzed under light microscopy by an experienced pathologist. The descriptive and semi-quantitative analysis included re-epithelization, inflammatory infiltrate and fibroblastic proliferation. Picosirius stained slides were used for descriptive analysis of the collagen fibers.

## RESULTS

### *Control, standard diet*

At the end of the experimental period, the wounds of animals fed with the standard diet were covered by typical epithelium. Subjacent to the epithelium, granulation tissue was seen that contained young fibroblast parallel to the surface. Blood vessel sprouts, usually hyperemic, and a moderate mononuclear inflammatory infiltrate were also observed. These cellular elements were distributed among bundles of mature collagen fibers regularly disposed in relation to the surface of the wound as shown by Picosirius stain (Figure 1).

### *Standard diet, laser therapy*

Wounds irradiated with the laser at a dose of 20J/cm<sup>2</sup> showed extensive ulceration in most cases, which were covered by a thick fibrin coagulum (crust). The

central area in two of the specimens showed epithelialization starting from the margins of the wound partially replacing the crust. Underlying the surface, there was an extensive area of granulation tissue rich in blood vessel sprouts mostly hyperemic. Young fibroblasts and mixed inflammatory infiltrate (Figure 2) were seen within an immature and irregularly distributed collagen matrix. Discrete interstitial edema was seen in 2 specimens. In one case, an abscess was present.

Increasing the dose to 40J/cm<sup>2</sup>, the specimens showed ulceration and crust of variable thickness in 4 cases, although in 2 specimens, there was epithelialization starting from the margins of the wound partially replacing the crust. In one specimen, the ulceration was free from crust. Underlying the area of ulceration, there was a large amount of granulation tissue containing neo-formed capillaries frequently hyperemic, young fibroblasts and mixed inflammatory infiltrate. In this case, granulation tissue was seen distending the fatty layer of the hypodermis. These elements were dispersed in an irregularly distributed collagen matrix in an advanced stage of maturation (Figure 3).

#### *Standard diet, polarized light*

When illuminated by the polarized light at a dose of 20J/cm<sup>2</sup>, the specimens showed the ulceration covered by a thick crust. Underlying this area, granulation tissue showed a large amount of blood vessels and

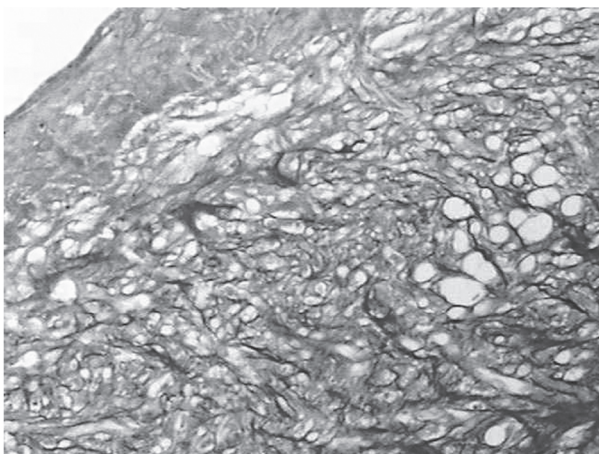


Figure 1. Photomicrography of nourished control specimen showing organized bundles of mature collagen fibers. Magnification: approximately 200X; Picrosirius.

hyperemic neo-capillaries; young fibroblasts parallel to the surface and a moderate mixed inflammatory infiltrate that sometimes distended the fatty layer were seen. These elements were dispersed in a more organized and more mature collagen matrix than the groups previously described (Figure 4).

Increasing the dose to 40J/cm<sup>2</sup> resulted in an area of ulceration covered by a crust of variable thickness. In one specimen, epithelialization was observed in almost the entire wound site. Underlying the area of ulceration, an extensive area of granulation tissue containing neo-capillaries, young fibroblasts, hyperemic blood vessels, and moderate mixed inflammatory infiltrate irregularly distributed in a collagen matrix discretely marked by Picrosirius staining was observed. This aspect probably represents an intermediate phase of maturation. The granulation tissue also distended the fatty layer of the hypodermis. In other areas free from inflammation, the tissue showed vacuolar degeneration.

#### *Control, DBR (undernourished)*

In undernourished subjects (untreated controls), the presence of ulceration covered by a crust of variable thickness was observed. Underlying this area, an extensive area of granulation tissue containing hyperemic neo-capillaries (Figure 5), a moderate number of young fibroblasts, and intense mixed inflammatory infiltrate dispersed in a large amount in an irregularly distributed

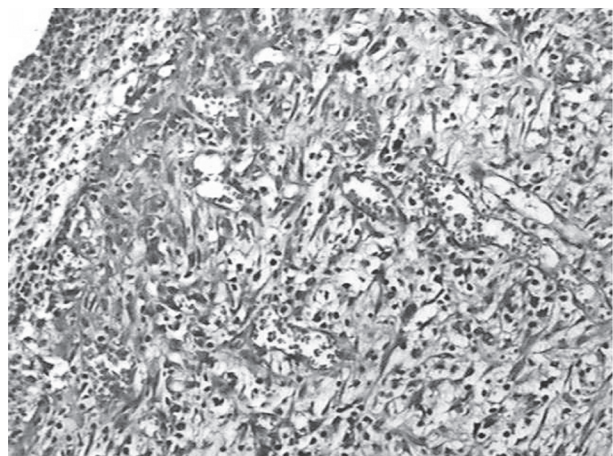


Figure 2. Photomicrography of nourished subject treated with 635nm laser light (20J/cm<sup>2</sup>) showing granulation tissue rich in congested blood vessels, fibroblasts and intense mixed inflammatory infiltrate. Magnification: approximately 200X; H&E.

collagen matrix in maturation, as shown by Picrosirius staining, were observed. In one of the specimens, the collagen fibers were not remarkably positive demonstrating that the tissue was quite immature. The granulation tissue reached the hypodermis. In 2 other specimens, areas of hemorrhagic exudate were observed.

#### *DBR and laser*

When irradiated with a dose of  $20\text{J}/\text{cm}^2$ , the wound was covered by epithelium of varied levels of

keratinization in 3 cases exhibiting a plane interface, free from skin appendices (Figure 6). Underlying this area, granulation tissue showed the presence of young fibroblasts placed parallel to the surface, hyperemic neo-capillaries and a moderate to intense predominantly chronic inflammatory infiltrate up to the hypodermis. These cellular elements in the dermis were distributed in a matrix containing bundles of collagen fibers, which were regularly organized in relation to the cutaneous surface (Figure 7) as shown by Picrosirius staining. Although in 2 cases ulceration was observed

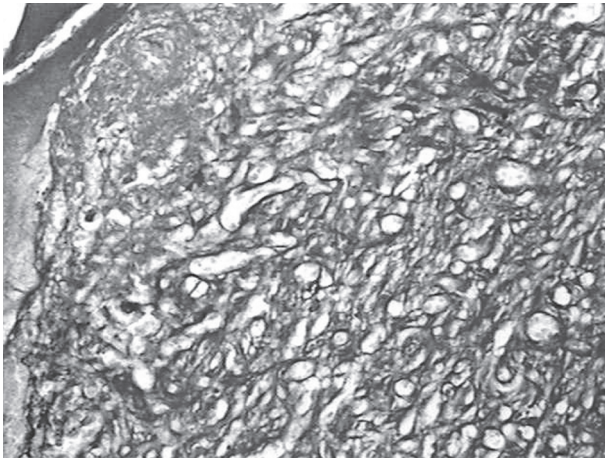


Figure 3. Photomicrography of nourished subject treated with  $\lambda 635\text{nm}$  laser light ( $40\text{J}/\text{cm}^2$ ) showing mature collagen fibers irregularly distributed. Magnification: approximately 200X; Picrosirius.

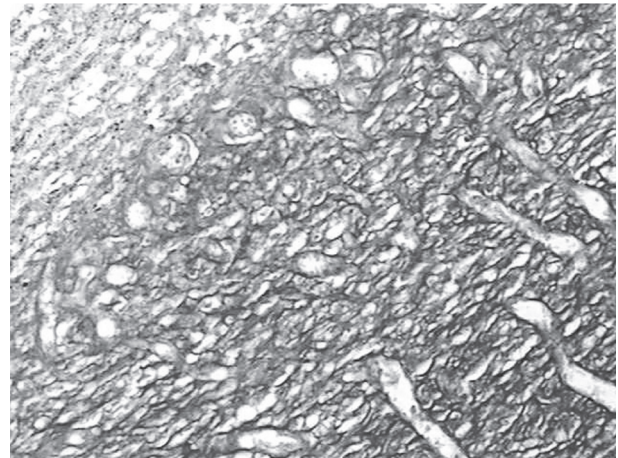


Figure 4. Photomicrography of nourished subject treated with polarized light ( $20\text{J}/\text{cm}^2$ ) showing bundles of collagen fibers in advanced phase of maturation. Magnification: approximately 200X; Picrosirius.

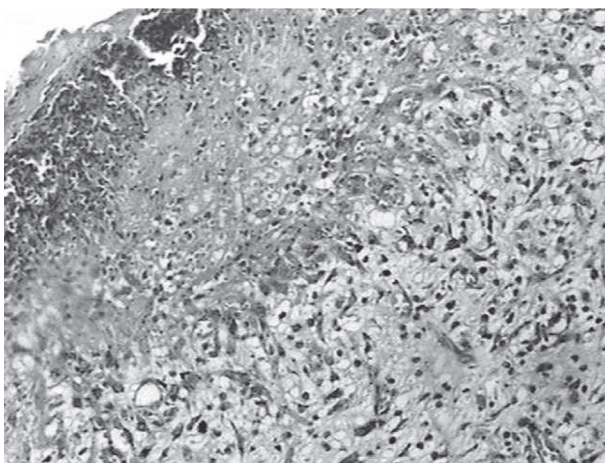


Figure 5. Photomicrography of undernourished control showing the wound covered by crust and the underlying granulation tissue containing some congested capillaries. Magnification: approximately 100X; H&E.

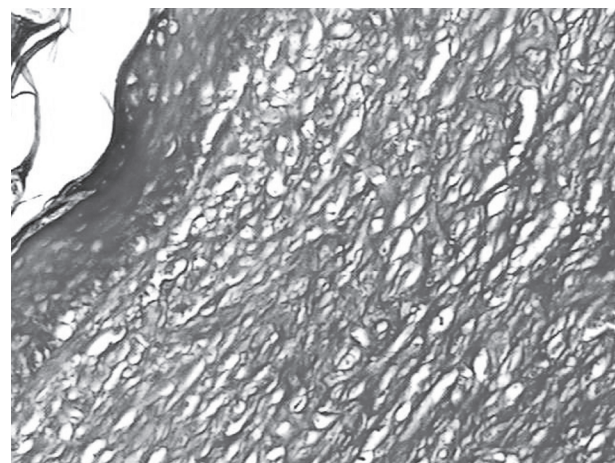


Figure 6. Photomicrography of undernourished subject treated with  $\lambda 635\text{nm}$  laser light ( $20\text{J}/\text{cm}^2$ ) showing mature bundles of collagen fibers regularly distributed in relation to the wound surface. Magnification: approximately 200X; Picrosirius.

covered by crust, in those initially observed there was also the presence of a thick crust besides the epithelialization.

Raising the dose to 40J/cm<sup>2</sup> resulted in a mostly keratinized epithelium free from skin appendices with a plane interface. Underlying this area, granulation tissue was seen, containing young fibroblasts parallel to the surface, hyperemic neo-capillaries and moderate to intense mixed inflammatory infiltrate (Figure 8) eventually extending to the hypodermis. The cellular elements described in the dermis were distributed in bundles of collagen fibers regularly organized in relation to the cutaneous surface and were in an advanced phase of maturation as shown by Picosirius staining. Although in 2 cases the surface presented ulceration covered by a crust, in those initially described there was also the presence of crust despite epithelialization of the wound.

#### *DBR and polarized light*

When illuminated with 20J/cm<sup>2</sup>, the surface of the wound was covered by epithelium usually keratinized exhibiting acanthosis and inter-papillary atrophies and absence of skin appendices and cytoplasmatic vacuolization. In one of the cases, epithelialization was observed, which was still covered by a crust.

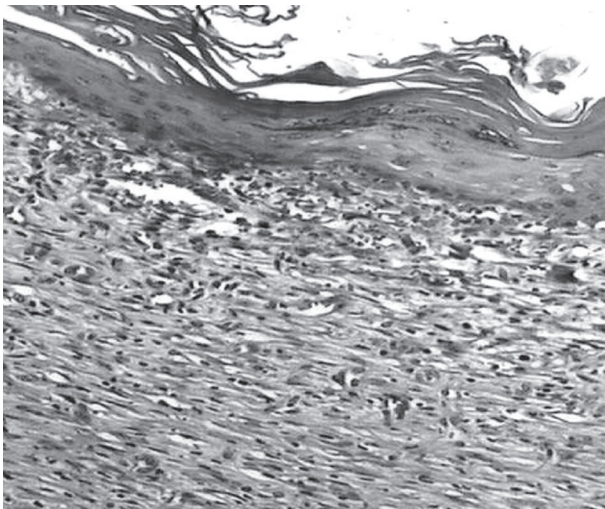


Figure 7. Photomicrography of undernourished subject treated with  $\lambda 635\text{nm}$  laser light (20J/cm<sup>2</sup>) showing the area covered by epithelium with plane interface. Magnification: approximately 200X; H&E.

Underlying this area, granulation tissue containing young fibroblasts parallel to the surface, neo-capillaries and predominantly mononuclear moderate inflammatory infiltrate extending sometimes to the hypodermis was observed. The granulation tissue showed a more discrete number of fibroblasts and the collagen matrix was more organized. One case showed extensive ulceration filled out by granulation tissue, a moderate number of young fibroblasts, hyperemic neo-capillaries, moderate to intense mixed inflammatory infiltrate, and intense interstitial edema. In this case, the collagen matrix was disorganized, but in maturation. In three other cases, the cellular elements were dispersed in a collagen matrix a little more organized and in maturation. In one case, the collagen deposit was very organized and in advanced phase of maturation.

Raising the dose to 40J/cm<sup>2</sup> resulted in keratinized epithelium, eventually ulcerated, covered by a crust sometimes exhibiting pseudoepitheliomatous hyperplasia. Underlying this area, granulation tissue containing young fibroblasts parallel to the surface, neo-capillaries and intense mononuclear inflammatory infiltrate were seen. These cellular elements were distributed in an organized collagen matrix in advanced maturation.

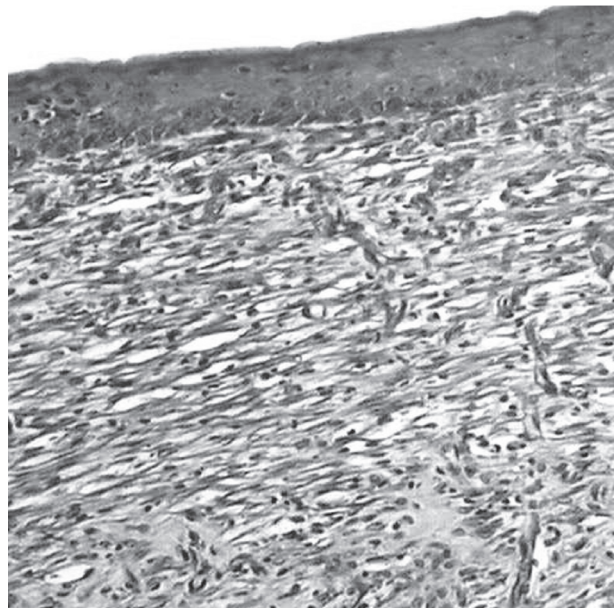


Figure 8. Photomicrography of undernourished subject treated with  $\lambda 635\text{nm}$  laser light (40J/cm<sup>2</sup>) showing fibroblasts and collagen fibers parallel to the surface, some capillary sprouts and moderate mixed inflammatory infiltrate. Magnification: approximately 200X; H&E.

## DISCUSSION

Nutritional deficiencies have a significant effect on the organism, including wound healing, altering tissue regeneration, inflammatory reaction, and immunological function, in other words, interfering at any point of the healing process. All malnutrition states will result in severe changes of the process of protein synthesis of the wound, besides stimulating greater collagen lysis (4).

Changes in diet are frequently necessary following extensive surgical procedures in the oral cavity due to surgical trauma. When impairment of the oral function is intense, parenteral feeding may be necessary. The use of dietary supplements is not always necessary after small surgeries in a patient who has appropriate diet (5).

In patients suffering from severe trauma or consumptive diseases, a considerable reduction in the levels of nutrients, especially proteins, can result in deficiencies of collagen synthesis. A delay in the differentiation and proliferation of fibroblasts at the wound site is also observed. Inversely, patients receiving a diet rich in proteins present faster wound healing (4,6).

Due to the effects that malnutrition has on the ability of the tissue to heal, in the present study an animal model that simulates severe undernourishment was used to assess the effect of phototherapy on wound healing. The use of light to stimulate wound healing is still very controversial in the literature. However, most authors agree that laser therapy possesses biomodulatory effects, improving scar formation and accelerating that process (7).

A comparison of the results of the present investigation with other reports is not an easy task as very few studies on this topic have been carried out. Galvão et al. (8) used the same undernourishment model to study the healing process in rats, but it was not possible to find any previous reports in which phototherapies were used in this model (7).

Most studies on the effects of phototherapies on the healing process have attributed the effects to several treatment parameters and properties of the light source used. Monochromaticity is one of the properties of laser light that has been suggested as an important factor of the final result; however, it seems that it is not the main factor as previous studies pointed out positive biomodulatory effects using different wavelengths (9-11).

Karu (9) affirmed that coherence is not important when photobiological effects are expected because both coherent and non-coherent light have been shown to be effective. Belkin and Schwartz (12) suggested that coherent light is not necessary as most biomodulatory effects are also obtained with the use of non-coherent light with appropriate wavelength.

Many previous studies tried to elucidate the true effect of coherence on the biological effects of phototherapies. Results of recent studies using cells in cultures began a discussion on the importance of the coherence of the light, as it showed no difference on the biological response between cultures treated with laser light, that is coherent, and the ones treated with a non-coherent light source. The distrust of the real need of the coherence of the light is increased by the fact that so far no definite explanation on the behavior of the coherence as light passes through the tissues has been given (13). The polarization characteristic, however, is neglected in most of the reports using laser therapy (14). This is the main reason why this form of phototherapy was included in the present investigation.

The wavelength of  $\lambda 635\text{nm}$  was used due to its superficial absorption because the literature mostly reports that higher wavelengths possess deeper penetration into the tissues. Different doses were also used due to conflicting results also reported in the literature. Despite of the large number of reports showing positive effects of laser therapy on wound healing, there are those that show inhibition or no effect of the healing (15). It is extremely important that correct protocols are developed for laser therapy and that they include the use of appropriate wavelength, dose, potency density, time of irradiation, as well as frequency and number of sessions as these parameters may have an influence on treatment outcome and avoid controversies and empirical conclusions.

In spite of the fact that most of the previous studies suggested an interval of 48 h, the protocol used in this study was to perform both treatments immediately after surgery and at 24-h intervals during 7 days. In order to compare different light sources, the use of the same timing is very important. Therefore, the protocol recommended by the manufacturer of Bioptron<sup>®</sup> was adopted (3). This did not interfere with laser therapy as daily applications show the same effects as 48-h intervals (16).

The macroscopic analysis of the wound healing

of subjects fed both diets is similar to previous reports (17); however, during the removal of specimens, it was evident that the wound was fragile in undernourished animals and had a tendency to dehiscence different from normally fed animals. This represents a clear weakness of the wound due to a poorer quality of tissue in undernourished animals.

Analysis of the epithelialization of nourished animals showed that when laser therapy was used at a dose of 20J/cm<sup>2</sup>, epithelialization was mostly complete at the end of the experimental period, different from that observed when a higher dose was used in which the epithelialization was incomplete in most cases. This suggested that dose influenced the outcome of the treatment and that smaller doses were more effective. This result, in spite of being in agreement with most of the previous studies, disagrees with the work of Mendez et al. (18) which found better results when higher wavelengths were associated with higher doses up to 50J/cm<sup>2</sup>. Therefore, the best optical parameter should be certain for the association of several factors as wavelength, dose, variety in the selection of the animal, wound type, evaluation method, and treatment conditions (19). No complete epithelialization was detectable at the end of the experimental time in nourished animals illuminated with polarized light and doses of 20J/cm<sup>2</sup> or 40J/cm<sup>2</sup>. This result agrees with the study by Nicola and collaborators (20), in which the groups treated with laser therapy presented better results when compared to those treated with polarized light. However, regarding this parameter, the experimental groups did not present results considered significantly better than the control groups, except the nourished group treated with 20J/cm<sup>2</sup> in relation to their control.

When analyzing the inflammatory infiltrate, nourished controls presented moderate chronic inflammation different from undernourished ones, who despite presenting moderate inflammatory infiltrate this was of mixed characteristic. Medeiros et al. (21) suggested that animals on low-protein diet show unfavorable disturbances in wound contraction and inflammation due to low levels of protein and they attributed an important role in the closing of open wounds to the nutritional status. The results of the present study also indicate that protein deficiency had a negative effect on the evolution of the inflammatory response.

When analyzing the experimental groups, a positive influence is evident of the phototherapy because

nourished animals illuminated with polarized light and undernourished subjects irradiated with  $\lambda$ 635nm laser light at a dose of 20J/cm<sup>2</sup> showed an inflammatory infiltrate considered moderate and chronic meaning a shorter resolution of the inflammation. In relation to the group irradiated with laser light, this aspect can represent an anti-inflammatory effect that might have initiated an early inflammatory response and that it was resolved more quickly than in the controls, agreeing with previous studies that showed an anti-inflammatory effect of the laser (11,19).

With relationship to the fact that the undernourished group irradiated with laser presented better effects than the nourished animals also irradiated may be explained by the fact that the photosensitivity of the cells to the laser is not of the type "everything or nothing". On the contrary, several degrees of responses may be triggered in cells that may be more or less sensitized, depending upon their physiologic status prior to irradiation. It is not surprising that laser therapy may not show an evident influence or show no effect at all on "healthy" subjects who are in physiologic balance.

Analyzing the fibroblastic proliferation, the results found in the present study showed that, in all groups, the fibroblasts proliferated, although this proliferation was more outstanding when the laser was used, a result that is in agreement with most of the literature (2,12,13), which shows that laser therapy, when used at appropriate doses, wavelength, potency density and time of exhibition, positively influences fibroblastic proliferation and production of collagen.

Analyzing the collagen of the healing wounds, differences were found between the control groups. Nourished subjects presented a more organized pattern of collagen fibers than the undernourished animals suggesting earlier maturation and larger proliferation of fibers. This result is in agreement with previous studies and indicated that nutritional deficiencies possess a strong effect on wound healing, altering tissue regeneration, inflammatory reaction and immunologic function.

Analysis of the results showed better results for nourished animals and undernourished animals illuminated with polarized light and a dose of 20J/cm<sup>2</sup> and the undernourished animals irradiated with laser light (20J/cm<sup>2</sup>). These groups showed collagen fibers parallel to the surface that were strongly marked by Picrosirius

staining. This means that there was a larger production of collagen fibers and a better organization of the tissue. In nourished animals illuminated or irradiated with a dose of 40J/cm<sup>2</sup>, an irregular organization of the fibers was seen. Despite strongly stained, the fibers did not present good organization.

Pinheiro and Frame (2) reported that laser therapy is used in Biomedicine because it improves tissue regeneration and healing, reduces postoperative pain and reduces inflammation. Increased production of collagen and fibroblastic proliferation, and an increase of local circulation are also observed when laser therapy is used.

The results of the present study suggest that the wavelength of 635nm resulted in a positive effect on the wounds, being more effective when 20J/cm<sup>2</sup> was used. Also, the effects were more detectable in the undernourished groups, which agrees with the literature that points out the effects of laser on cells with some level of deficiency. The polarized non-coherent light of Bioptron® showed a positive effect that was more evident in nourished subjects, a result different from that found with laser light.

It is concluded that the nutritional status influenced the progression of the healing process as well as the quality of the healed tissue and that the use of both modalities of phototherapy resulted in a positive biomodulatory effect in both nourished and undernourished animals. The effect of the polarized light was more evident in nourished animals and laser therapy was more effective in the treatment of undernourished animals, in both cases at a dose of 20J/cm<sup>2</sup>.

## REFERENCES

- Burgess LP, Morin GV, Rand M, Vossoughi J, Hollinger JO. Wound healing - Relationship of wound closing tension to scar width in rats. *Arch Otolaryngol Head Neck Surg* 1990;116:798-802.
- Pinheiro ALB, Frame JW. Laser em Odontologia. Seu uso atual e perspectivas futuras. *RGO* 1992;40:327-332.
- BIOPTON AG. Users Manual. 2000. Switzerland.
- Corsi RCC, Corsi PR, Pirana S, Muraco FAF, Jorge D. Cicatrização das feridas - revisão da literatura. *Rev Br Cir* 1994;84:17-24.
- Mahan L, Arlin MT, Krause SE-S. Alimentos, Nutrição e Dietoterapia. 8th edn. São Paulo: Rocca. 1996.
- Jahson S, Gerdin B. Anastomic healing of small bowel with or without chronic radiation damage in protein-deficient mal-nourished rats. *Eur J Surg* 1996;162:47-53.
- Conlan MJ, Rapley JW, Cobb CM. Biostimulation of wound healing by low-energy laser irradiation - A review. *J Clin Periodontol* 1996;23:492-496.
- Galvão CBC, Pinheiro ALB, Pessoa DCNP. Comparação da cicatrização de feridas bucais em animais submetidos às dietas: DBR X dieta balanceada acrescida de suplemento alimentar. *Rev Br Med* 2000;57:884-850.
- Karu TI. Photobiological fundamentals of low power laser therapy. *J Quant Electro* 1987;10:1703-1717.
- Abergel RP, Lyons RF, Castel JC, Dwyer RM, Uitto J. Biostimulation of wound healing by lasers: Experimental approaches in animal models and in fibroblast cultures. *J Dermatol Surg Oncol* 1987;13:127-133.
- Al-Watban FAH, Zhang XY. The acceleration of wound healing is not attributed to laser skin transmission. *Laser Therapy* 2000;12:3-11.
- Belkin M, Schartz M. New biological phenomena associated with laser radiation. *Health Phys* 1989;56:687-690.
- Schindl A, Schindl M, Pernerstofer-Schon H, Mossbacher U, Schindl L. Low-intensity laser therapy: A Review. *J Invest Med* 2000;48:312-326.
- Ribeiro MS, Teixeira D, Maldonado EP, de RW, Zezell DM. Effects of 1047nm Neodymium laser radiation on skin wound healing. *J Clin Laser Med Surg* 2002;20:37-40.
- Houghton PE, Brown JL. Effect of low level laser on healing in wounded fetal mouse limbs. *Laser Therapy* 1998;11:11-12.
- Pinheiro ALB, Nascimento SC, Vieira ALB, Brugnera Jr A, Zanin FA, Rolim AB, Silva OS. Effects of low-level laser therapy on malignant cells: In vitro study. *J Clin Laser Med Surg* 2002;23-26.
- Bucknall TE, Ellis H. Wound Healing for Surgeons. 1st edn. London: Baillere Tindall. 1984; p 3-28.
- Mendez TMV, Pinheiro ALB, Pacheco MT, Nascimento PM, Ramalho LM. Dose and wavelength of laser light have influence on the repair of cutaneous wounds. *J Clin Laser Med Surg* 2004;22:19-25.
- Rigau J. Acción de la luz láser a baja intensidad en la modulación de la función celular. Reus. [Doctorate thesis]. Facultad de Medicina i Ciència de la Salut. Univ. Rovira i Virgili; 1996.
- Nicola JH, Nicola EM, Ribeiro MS, Paschoal JR. Role of polarization of coherence of laser light on wound healing. Laser tissue interaction. Jacques VSL ed. Proceedings of SPIE 1994;2134: 448-450.
- Medeiros AC, Freire TMGL, Pinto JR, Fel. O açúcar e a solução de nutrição parenteral no tratamento das feridas infectadas. *Rev Br Cir* 1991;81:11-14.