

Actinomyces-like organisms in the cervical Papanicolaou-stained smears of intrauterine device (IUD) users

Zélia da Costa¹

Nélia Maria Cunha Ruas²

Carlito Lopes Nascimento Sobrinho²

Gustavo Göhringer de Almeida Barbosa³

Moysés Sadigursky⁴

Aryon de Almeida Barbosa Júnior⁵

Abstract

The prevalence of Actinomyces-like organisms in cervicovaginal smears of 2,347 Brazilian women, including 151 (6.4%) intrauterine devices (IUD) users for at least six months and as controls 2,196 (93.6%) non-wearers of similar age using hormonal, barrier, or other contraceptive methods or none, living in Salvador, Bahia, has been investigated. Cervical smears were stained by the Papanicolaou method for the microscopic examination of Actinomyces-like organisms. The relationship between Actinomyces-like organisms infection and contraceptive methods, age and number of sexual partners has been analyzed. The result showed that the overall detection rate of Actinomyces-like organisms in 2,347 women was 0.17%. The detection rates in IUD users and non-users were 1.32% and 0.09% respectively. The prevalence rate (1.32/0.09) was of 14.7, indicating a risk fourteen times greater for the presence of Actinomyces-like organisms in cervical smears of IUD users. No contraceptive methods were used by 43% of the patients. Most patients were between 21 and 30 years old, having 3-5 sexual partners.

Keywords: Actinomycosis. IUD. Cervix. Cervicovaginal smear.

INTRODUCTION

Actinomycosis is a slowly progressive bacterial infection that characteristically expands through anatomic structures and can lead to fistulae and abscesses. Manifestations of this disease may mimic cancer, inflammatory bowel disease, or diverticulitis and because this, the diagnosis is often delayed. Pelvic and abdominal actinomycosis is a chronic suppurative granulomatous disease caused by a delicate slow

growing anaerobic or microaerophilic non-spore-forming, Gram positive branching bacteria of low pathogenicity, *Actinomyces* species (EVANS, 1993; VAN DE LANDE; SPANJAARD; BURGUER, 2003; CHATTI et al., 2003). *Actinomyces israeli* is the species most commonly associated with pelvic colonization or infection (DUGUID, 1983). The organism may either be pathogenic or commensal,

¹ Sociedade Baiana de Citopatologia

² Universidade Estadual de Feira de Santana

³ Escola Baiana de Medicina e Saúde Pública

⁴ Universidade Federal da Bahia

⁵ Centro de Pesquisas Gonçalo Muniz – Fiocruz/BA

Correspondência para / Correspondence to:

Aryon de Almeida Barbosa Júnior
R. Valdemar Falcão, 121-Brotas
40295-001 Salvador- Bahia - Brasil
Tel.: (071) 3356-8788, r 207
E-mail: aryon@cpqgm.fiocruz.br

depending on the presence of leukocytes. This and other species of *Actinomyces* is commonly a commensal organism of the normal flora of the oropharynx and the gastrointestinal tract in humans (TREVINO SALINAS et al., 2003), but not the genital tract.

Pelvic actinomycotic disease occurs infrequently, but when it does the right ovary and fallopian tube are generally involved (EVANS, 1993). It is indistinguishable from other forms of pelvic inflammatory disease. In spite of the fact that histologically and bacteriologically verified cases of pelvic actinomycosis are rare, a review of the literature shows that the abdominal-pelvic form has been increasing over the past 10 years secondary to the increased and prolonged use of an intrauterine device (IUD) (DUGUID, 1983; CIRAFICI; WORRETH; FROEHLICH, 2002). The continuing presence of an IUD, which is a foreign body, is frequently associated with increasing colonization of the cervix with aerobic and anaerobic organisms, among which growth of actinomycetes have been identified (EVANS, 1993). It appears that plastic inert IUDs are associated with a greater prevalence of *Actinomyces* infection than are copper-bearing IUDs (DUGUID, 1983; EVANS, 1993) and in women who have had an IUD for more than four years (EVANS, 1993). Prior to the introduction of the plastic IUD, documented cases were mainly associated with large bowel disease.

Clinically, pelvic actinomycosis usually presents as a low smoldering infection. The initial symptoms that warn of infection of the genital tract are often mild and include abdominal pain; slight fever, nocturnal chills or sweats; vaginal discharge; inter-menstrual bleeding; and increased menstrual bleeding. Offensive discharge, pelvic tenderness, or a mass may develop late, and occasionally the patient is hospitalized with a ruptured pelvic abscess, generally unilateral, which can be fatal (DUGUID, 1983). Traditional ways of identification of anaerobic Gram-positive non-sporulating bacilli by isolation of the organism and studying it phenotypically by elucidation of its morphologic and biochemical

characteristics and metabolic end products are associated with a need for special equipment and expertise (WOO et al., 2002). However, the *Actinomyces* are easily identifiable with the Gram stain. A Pap smear can also detect the presence of *Actinomyces* organisms, which are seen as branching filaments, sulfa granules or irregular islands of amorphous material, which stain blue to brown or black. Culture techniques tend to be inadequate and identification is a problem unless measures are taken to inhibit the growth of more robust and fast growing anaerobes by metronidazole and a dilution technique; so many health professionals use a microscope to identify *Actinomyces israelii* (EVANS, 1993) and often confirm the microscopy findings with direct immunofluorescent techniques.

The purpose of this study was to determine the frequency of detecting *Actinomyces*-like organisms in the cervical cytological smears from women using IUD and from women without IUD using other contraceptive methods or none in Salvador, Northeastern Brazil.

MATERIAL AND METHODS

To determine the frequency of detecting the occurrence of *Actinomyces*-like organisms in cervico-vaginal cytological smears, in the files of the Sociedade Baiana de Citopatologia (Sobaci) collected from Paripe, Salvador, Bahia State, Brazil between 1999 and 2001, we retrospectively reviewed the data base of 2,347 cervico-vaginal Pap smears. This study involved 2,347 women [151 (6.4%) women who had used IUDs for at least 6 months and 2,196 (93.6%) women as controls of similar age without IUDs using hormonal contraceptives, barrier contraceptives, or other contraceptive methods, or even none].

Cervico-vaginal smears were screened for other purposes to detect inflammation, reparative cellular changes (both in columnar and squamous cells), histiocytes, endometrial cells, and finally, cervical intraepithelial neoplasias (CIN) grades I, II, and III, but these data are not reported here.

The majority of cervical cytology specimens were obtained from each patient as both direct cervical scrapes and endocervical brushings and sub-designated as such. Cytology specimens were prepared as alcohol-fixed and stained by the Papanicolaou method for the microscopic examination of *Actinomyces*-like organisms. Morphological criteria for the cytologic diagnosis of *Actinomyces*-like organisms in the PAP-stained cervical smears were the presence of characteristic basophil spots surrounded by intertwined filament-type formation (FIGURE 1a; FIGURE 1b). The relationship between *Actinomyces*-like organisms infection and contraceptive methods, age and number of sexual partners were analyzed.

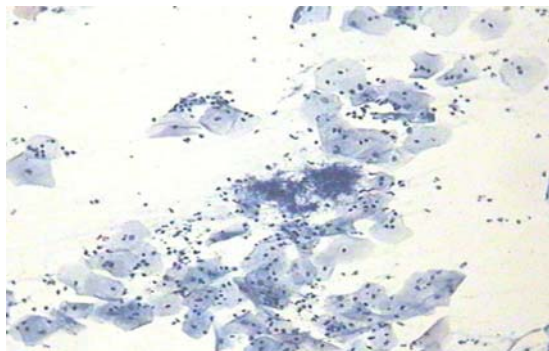


Figure 1a - Round-to-oval conglomerations of filamentous branching microorganisms (*Actinomyces*-like organisms) in a Papanicolaou-stained smear with characteristic basophil spots - 20X.

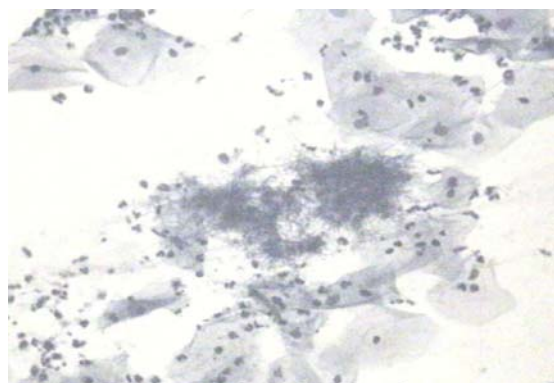


Figure 1b - Round-to-oval conglomerations of filamentous branching microorganisms (*Actinomyces*-like organisms) in a Papanicolaou-stained smear with characteristic basophil spots - 40X.

RESULTS

Clinical features

The age of the patients were 35.2 ± 12.2 (the youngest was 12 and the oldest was 82 years old). The mean number of pregnancies related by the patients was 3.2 ± 3.1 (maximum 23): 0-2 in 50.2%; 3-5 in 32.6%; more than 6 in 17%. The mean number of sexual partners were 3.8 ± 2.4 (minimum one and maximum 23), with 72% having sexual relations with 3 to 5 partners.

The contraceptive methods used were: none in 1,109 (47.3%) of the patients; bilateral tubal ligation (BTL) in 549 (23.4%) of the patients; pill in 393 (16.7%) of the patients; IUD in 151 (6.4%) of the patients; condom in 136 (5.8%) of the patients; other methods in 9 (0.4%) of the patients. No follow-up was available. None had repeated cervico-vaginal smears and none underwent biopsy.

Cytological findings

The result showed that the overall detection rate of *Actinomyces*-like organisms in 2,347 women was 0.17%. The detection rates in IUD wearers and non-wearers were 1.32% and 0.09% respectively. The prevalence rate (1.32/0.09) was of 14.7, indicating a risk fourteen times greater for the presence of *Actinomyces*-like organisms in cervical smears of IUD users.

DISCUSSION

Intrauterine devices are simple and highly effective (less than 1% of IUD users become pregnant), long-term methods of contraception without the need for patient compliance. It is not rendered ineffective by other drugs, as maybe steroid contraceptives, and its side effects, for carefully selected patients, are considered by most practitioners to be acceptably low (VAN KETS et al., 1989), but most IUD users face heavy menstrual loss. Irritation and pressure cause endometrial changes (e.g., a local inflammatory cell response) in most IUD users. Nonspecific, noninfectious cervicitis is more common in women using IUDs than in women

using other contraception. However, pelvic inflammatory disease (PID) is a well-documented complication of IUD use (JAMAL et al., 1983). In the presence of any type of IUD, regardless of the duration of use, actinomycetes have been reported with increasing frequency in routine cervical smears of women who have been almost or totally symptom free (DUGUID, 1983). Nevertheless, this relationship is at best tenuous and actinomycosis is not the only bacterial infection caused by IUD use. (ATALLAH, et al., 1999)

Detection rates of *Actinomyces*-like organisms on Papanicolaou smear are somewhat variable; but the use of other detection methods, including endometrial biopsy, culture, and immunofluorescence, did not improve this variability (TENDOLKAR et al., 1993). 2.8-11.6% of cervical smears of IUD users with no predisposing factors show *Actinomyces*-like organisms. Other reports estimated the overall prevalence of *Actinomyces* showing up on Pap smears of IUD users at 80% to 90% of IUD users (ESCHENBACH, 1981). In the present study of Papanicolaou smear-based detection, however, the frequency was lower (1.32%). Our data, confirmed yet that there is a risk many times greater for the presence of *Actinomyces*-like organisms in cervical smears of IUD users than in women using other contraceptive methods. Women with multiple partners, happening often in the studied population, could also have enhanced the risk.

In spite of the fact that the disease caused by *Actinomyces spp.* is often of difficult diagnosis (BURLANDO et al., 2001), scarce evidence suggests that there is a cause-and-effect relationship between IUD use and pelvic actinomycosis (EVANS, 1993; BURLANDO et al., 2001). However, it is difficult to predict which IUD users harboring *Actinomyces israelii* will develop subsequent serious PID (EVANS, 1993). Even though some studies suggest that IUDs increase the risk of pelvic infection, the increase occurs only in the first few months after insertion (BUCKLEY, 1994). Moreover, the resulting concerns about PID related to IUDs use limited their application throughout the world (TSANADIS et al., 2002).

Infection can begin principally in three ways: 1) when endogenous *Actinomyces* penetrate damaged tissues following trauma, 2) other infections of foreign bodies, or 3) surgical manipulation (VILLANI et al., 1987). Although the exact origin and routes by which the *Actinomyces* arrive in the vagina are unknown. There are two mechanisms described by which organisms from the vaginal pool and lower endocervical canal can spread throughout the genital tract. There is increasing evidence that the presence of tails on the IUDs appears to facilitate the ascent of organisms from the vagina into the body of the uterus (JAMAL et al., 1983; DUGUID, 1983). Also, calcium encrustation and disintegration of the IUD, which at times occur after prolonged use, results in migration of fragments of calcium encrusted plastic throughout the genital tract. These form niduses for colonization of actinomycetes and other organisms.

The consequences and management of asymptomatic *Actinomyces*-like organisms detected on cervical cytologic smears continue to be controversial (DEHAL et al., 1998). When *Actinomyces*-like organisms are found in cervical smears and the finding is confirmed by Gram stain or by culture and/or immunofluorescence, the patient should be informed in general terms (DUGUID, 1983). Treatment suggestions depend on whether the patient has symptoms or is asymptomatic, and whether the presence of the organism represents an infection or colonization. However, the presence of *Actinomyces* in IUD wearers warrants removal of the device, if necessary under antibiotic cover (VILLANI et al., 1987; CIRAFICI; WORRETH; FROEHLICH, 2002; VAN DE LANDE; SPANJAARD; BURGUER, 2003). Sometimes a combination of both is indispensable to achieve complete recovery.

There are no final answers yet as to the prevention and management of *Actinomyces* infection and colonization associated with long-term use of IUDs. Nevertheless, routine cervical examinations are important for women who are IUD users (IWASAKI et al., 2003), to identify the presence of *Actinomyces*-like organisms and eventually stage sub-clinical infections.

Organismos semelhantes a Actinomyces em esfregaços cérvico-vaginais de usuárias de dispositivo intra-uterino (DIU)

Resumo

Foi investigada a prevalência de organismos semelhantes a *Actinomyces* em esfregaços cérvico-vaginais de 2.347 mulheres brasileiras, incluindo 151 (6,4%) portadoras de dispositivo intra-uterino (DIU) por pelo menos seis meses; e como grupo controle 2.196 (93,6%) mulheres não portadoras de DIU, com idade similar, usando métodos contraceptivos diversos (hormonais, de barreira e outros) ou nenhum, morando em Salvador, Estado da Bahia. Os esfregaços cervicais foram corados pelo método de Papanicolaou para exame microscópico de organismos semelhantes a *Actinomyces*. A relação entre a presença de organismos semelhantes a *Actinomyces* e métodos contraceptivos, idade e número de parceiros sexuais, foi analisada. O resultado mostrou que a taxa total de detecção de organismos semelhantes a *Actinomyces* em 2.347 mulheres foi de 0,17%. As taxas de detecção em usuárias e não usuárias de DIU foram 1,32% e 0,09% respectivamente. A razão de prevalência (1,32/0,09) foi de 14,7, indicando um risco quatorze vezes maior para a presença de organismos semelhantes a *Actinomyces* em esfregaços cérvico-vaginais de usuárias de DIU. Nenhum método contraceptivo era usado por 43% das pacientes. A maioria delas tinha entre 21-30 anos de idade, e 3-5 parceiros sexuais.

Palavras-chave: Actinomicose. DIU. Cérvix. Esfregaço cérvico-vaginal.

REFERENCES

- ATALLAH, D. et al. Genital actinomycosis: diagnostic and therapeutic difficulties: report of three cases. *Ann. Chir.*, Paris, v.53, n.4, p.291-296, 1999.
- BUCKLEY, C.H. The pathology of intra-uterine contraceptive devices. *Curr. Top. Pathol.*, Berlin, v.86, p.307-330, 1994.
- BURLANDO, S.C. et al. Ovarian abscess due to *Actinomyces* sp. in absence of an intrauterine contraceptive device. *Medicina (B. Aires)*, Buenos Aires, v.61, n.5, pt. 1, p.577-580, 2001.
- CHATTI, S. et al. Endometrial actinomycosis: two case reports. *Tunis Med.*, Tunis, v.81, n.1, p.63-66, 2003.
- CIRAFICI, L.; WORRETH, M.; FROEHLICH, F. Pelvic and abdominal actinomycosis: case report and review of the literature. *Rev. Med. Suisse Romande*, Lausanne, v.122, n.11, p.535-537, 2002.
- DEHAL, S.A. et al. Clinically inapparent tuboovarian actinomycosis in a woman with an IUD: a case report. *J. Reprod. Med.*, St.Louis, v.43, n.7, p.595-597, 1998.
- DUGUID, H.L. Actinomycosis and IUDs. *IPPF Med. Bull.*, London, v.17, n.3, p.1-2, 1983.
- ESCHENBACH, D. Actinomyces in IUD users: management, prevention sparks controversy. *Contracept. Technol. Update*, Atlanta, v.2, n.3, p.29-32, 1981.
- EVANS, D.T. Actinomyces israelii in the female genital tract: a review. *Genitourin. Med.*, London, v.69, n.1, p.54-59, 1993.
- IWASAKI, M. et al. A case of ovarian actinomycosis. *Infect. Dis. Obstet. Gynecol.*, New York, v.11, n.3, p.171-173, 2003.
- JAMAL, F. et al. Actinomyces-like organisms in the cervical smears of IUCD users. *Malays. J. Reprod. Health*, Kuala Lumpur, v.1, n.1, p.55-59, 1983.
- TENDOLKAR, U. et al. Actinomyces species associated with intrauterine contraceptive devices and pelvic inflammatory disease. *Indian J. Pathol.Microbiol.*, Belgaum, v.36, n.3, p.238-244, 1993.
- TREVINO SALINAS, E.M. et al. Pelvic actinomycosis in menopausal patient: case review. *Ginecol. Obstet.Mex.*, México, v.71, p.532-536, 2003.
- TSANADIS, G. et al. Bacteriological cultures of removed intrauterine devices and pelvic

inflammatory disease. **Contraception**, New York, v.65, n.5, p.339-342, 2002.

VAN DE LANDE, J.; SPANJAARD, L.; BURGER, M.P. Two women with a chronic process in the lower abdomen. **Ned. Tijdschr. Geneesk.**, Amsterdam, v.147, n.48, p.2357-2360, 2003.

VAN KETS, H.E. et al. Long-term experience with multiload intrauterine devices. **Adv. Contracept.**, Dordrecht, v.5, n.3, p.179-188, 1989.

VILLANI, U. et al. Actinomycosis of bladder and intrauterine devices. **Br. J. Urol.**, Oxford, v.60, n.5, p.463-464, 1987.

WOO, P.C. et al. Diagnosis of pelvic actinomycosis by 16S ribosomal RNA gene sequencing and its clinical significance. **Diagn. Microbiol. Infect. Dis.**, New York, v.43, n.2, p.113-118, 2002.

Recebido em / *Received*: 16/11/2004

Aceito em / *Accepted*: 20/01/2005