

A Preliminary Report on the Effect of Laser Therapy on the Healing of Cutaneous Surgical Wounds as a Consequence of an Inversely Proportional Relationship between Wavelength and Intensity: Histological Study in Rats

PATRÍCIA MARIA DO NASCIMENTO, M.S.,¹ ANTONIO LUIZ B. PINHEIRO, Ph.D.,^{1,2}
MIGUEL ÂNGELO CASTILHO SALGADO, Ph.D.,³ and
LUCIANA MARIA PEDREIRA RAMALHO, Ph.D.²

ABSTRACT

Objective: The objective of the present investigation was to assess the histological effects of different wavelengths and intensities on the healing process of cutaneous wounds. **Background Data:** Tissue repair is a dynamic interactive process which involves mediators, cells and extra-cellular matrix. Several reports on the use of laser therapy have shown that the healing process is positively affected when the correct parameters are used. **Methods:** Eighteen standardized wounds were surgically created on the dorsum of male and female *Wistar* rats, which were subsequently divided into two experimental groups according to wavelength used (λ 670 or λ 685 nm) for lasertherapy (LLLT). Each group was divided into three subgroups of three animals according to the intensity of the applied irradiation (2, 15, or 25 mW). Twelve animals were used as untreated controls and were not irradiated. The irradiation was carried out during seven consecutive days. The animals were sacrificed eight days after surgery. The specimens were removed, kept in 4% formaldehyde for 24 h, routinely prepared to wax, stained with H&E, and analyzed under light microscopy. **Results:** For both groups, light microscopy showed a substitution repair process; however, when LLLT was used, a positive biomodulatory effect was detectable, chiefly associated with shorter wavelength and low intensity. **Conclusions:** The results of the present study indicate that LLLT improved cutaneous wound repair and that the effect is a result of an inversely proportional relationship between wavelength and intensity, with treatment more effective when combining higher intensity with short wavelength or lower intensity with higher wavelength.

INTRODUCTION

TISSUE REPAIR is a dynamic interactive process, which involves several biochemical and cellular changes.^{1–3} Wound healing events can be divided into three phases: inflammation, granulation tissue formation and both deposition and remodeling of the extra-cellular matrix.⁴ It is accepted that factors which influence the healing process also affect the final aspect of the scar as and as its mechanical properties. Many studies

involving the use of low-level lasertherapy (LLLT) have shown that the healing process is enhanced by such therapy.^{5–11}

The biological effects of the LLLT have been attributed to several factors such as monochromaticity,^{11,12} fluence,^{7,13,14} as well as of the phase of cellular growth in which the cells are irradiated.^{15–17} LLLT has been used in many medical and dental specialties.^{5,6,14,18} Recent studies indicate that the wavelength and specific energy density modulate the metabolism of tissue both *in vivo*^{19,11,13,19} and *in vitro*.^{8,20–22} Besides the effects on

¹IPD, Univap, São Jose dos Campos, São Paulo, Brazil.

²Laser Center, School of Dentistry, Federal University of Bahia, Salvador, Bahia, Brazil.

³School of Dentistry, São Paulo State University, São Jose dos Campos, São Paulo, Brazil.

wound healing,^{13,16,19,22} LLLT results in an analgesic effect,^{12,14} reduces edema, prevents infections,^{17,24} and affects nerves.^{12,13}

MATERIALS AND METHODS

The Ethics Committee of the University of the Vale do Paraíba (UNIVAP) approved this work. Thirty young adults male Wistar rats weighing 200–250 g obtained from the Animal House of the University of São Paulo at Ribeirão Preto were kept in individual cages in environmental conditions of temperature and brightness, fed with pelted laboratory diet and had water ad libitum throughout experimental time. The animals were submitted to the surgical procedure and LLLT at the Institute for Research and Development—IP&D—University of the Vale do Paraíba under general anesthesia (intraperitoneal injection of 0.1ml/100g of Zoletil®). The back of the animals were shaved, washed with saline and dried with sterile gauze. One standardized circular wound measuring 8×1 mm was created on the dorsum of each animal using a round punch. The animals were divided into two groups containing 15 animals each (15 wounds). These groups were divided into three subgroups containing five animals each (five wounds). When appropriate, three animals were irradiated (three wounds) and two acted as controls (two wounds). The wounds were irradiated with a diode laser on a daily basis always at the same time ($\lambda 670$ nm or $\lambda 685$ nm, 50 mW. $\phi \sim 0.0028$ cm², Thera Lase®, DMC, São Carlos, SP, Brazil) with total dose per session of 10 J/cm² given at varying intensities (2, 15, or 25 mW). Irradiation was performed transcutaneously on four points 2 mm of the border of the wound, fractionating the dose of each session. The equipment according to the intensity used automatically adjusted irradiation time. A summary of the treatment can be seen on Table 1. The animals were humanely killed with an overdose of intraperitoneal general anesthetic at the eighth day after the surgery. The specimens were removed, coded, kept in 4% formaldehyde during 24 hours and routinely processed to wax cut and stained with H&E and examined under light microscopy by an experienced pathologist at the Laboratory of Oral Pathology of the School of Dentistry of the Federal University of Bahia. The pathologist was not informed of the meaning of the coding of the specimens. Edema, hyperemia, inflammatory infiltrate and the presence and distribution of fibroblasts were used as qualitative parameters for evaluation of the healing process.

RESULTS

At the end of the experimental period all wounds showed the presence of a crust composed of a coagulated eosinophilic fib-

TABLE 1. TREATMENT SUMMARY

Intensity	Wavelength		
	2 mW	15 mW	25 mW
670 nm	3	3	3
685 nm	3	3	3
Control	4	4	4

rous exudate that was predominately neutrophilic. On control subjects the presence of granulation tissue richly vascularized and strongly hyperemic with the presence of a moderate mononuclear inflammatory infiltrate and discrete and diffuse fibroblastic proliferation containing cells with fusiform or oval nuclei was observed below the wound surface (Fig. 1).

On irradiated specimens ($\lambda 670$ nm, 2 mW) granulation tissue was characterized by an intense angioblastic proliferation, with the extensive presence of congested capillaries predominantly on the superficial portions of the wound. Exuberant fibroblastic proliferation mainly of young fibroblasts displaying oval nuclei and mature cells whose nuclei were flat was observed seven days after surgery (Fig. 2). A discrete beginning of re-epithelialization of the ulcer was also observed. Increasing the intensity to 15 mW also resulted in intense angioblastic proliferation with the presence of a predominantly mononuclear inflammatory infiltrate more intense than that observed with 2 mW (Fig. 3). Further increasing the intensity to 25 mW caused re-epithelialization of the wound on most subjects. Granulation tissue was characterized by intense proliferation of mature fibroblasts distributed in a dense connective tissue. Neovascularization was less evident than that observed when lower intensities were used. There was a discrete presence of a mononuclear inflammatory infiltrate, also of smaller intensity (Fig. 4).

When using the $\lambda 685$ nm (2 mW) the dermis showed a moderate angioblastic proliferation and less hyperemia than in the group irradiated with $\lambda 670$ nm laser. In addition to intense fibroblastic proliferation, there was a diffuse and moderate mono-




FIG. 1. Photomicrography of control specimen. Observe crust on the surface of the granulation tissue, which is characterized by a moderate mononuclear inflammatory infiltrate and discrete fibroblastic proliferation. H&E, approx. $\times 200$.

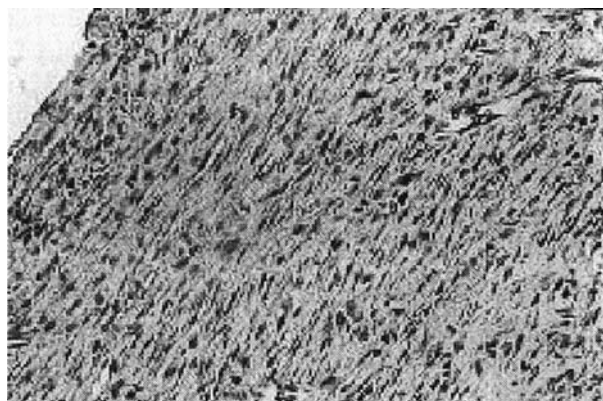


FIG. 2. Photomicrography of specimen irradiated with $\lambda 670$ nm laser (2 mW). It is observed that the granulation tissue is characterized by intense fibroblastic proliferation. Fibroblasts are characterized by oval or fusiform nucleus. H&E, approx. $\times 400$.

nuclear inflammatory infiltrate. In the epidermis, discreet re-epithelialization of the wound was observed (Fig. 5). When increasing the power to 15 mW, neovascularization was noticed in the dermis and there was prevalence of mature fibroblasts distributed in a connective tissue richer in collagen fibers than observed on the subjects irradiated with $\lambda 670$ nm laser, except for the group irradiated with 25 mW. In the epidermis, epithelial cells were observed covering the surface of most specimens (Fig. 6). Increasing the intensity to 25mW resulted in a poor vascular-

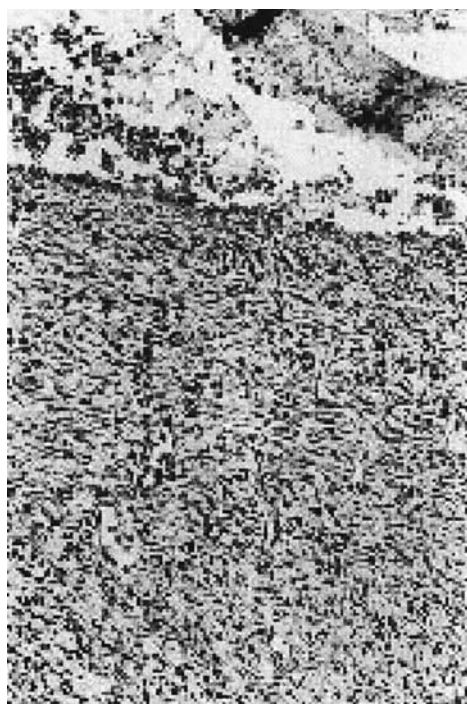


FIG. 3. Photomicrography of specimen irradiated by $\lambda 670$ nm laser (15 mW). It is observed a ulceration limited by granulation tissue, showing also hyperemia. H&E, approx. $\times 100$.

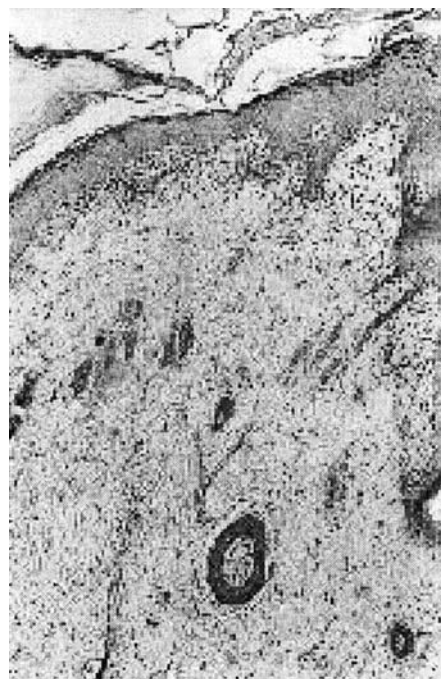


FIG. 4. Photomicrography of specimen irradiated by $\lambda 670$ nm laser (25 mW). It is observed a crust completely covering the area of re-epithelialization. H&E, approx. $\times 100$.

ized granulation tissue. Predominant presence of young fibroblasts and inflammatory cells, characterizing advanced healing was seen on the dermis (Fig. 7). However, the most significant characteristic aspect of this group was the presence of adipocytes distributed within the dermis and that was not restricted to deeper portion of the tissue as routinely observed (Fig. 8).

DISCUSSION

Different parameters for LLLT were used in previous studies of wound healing which explains the conflicting results reported. In the present investigation, two different wavelengths,

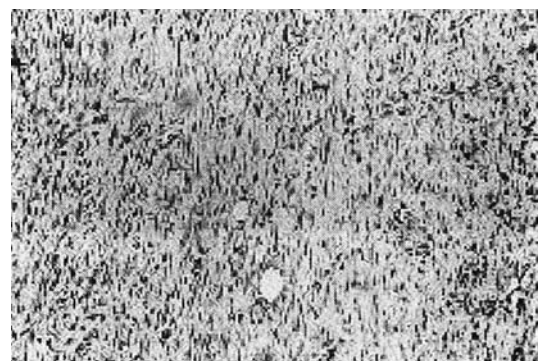


FIG. 5. Photomicrography of specimen irradiated by $\lambda 685$ nm laser (2 mW). It observed intense fibroblast proliferation. Fibroblasts show oval or fusiform nucleus. Presence of moderate mononuclear inflammatory infiltrate. H&E, approx. $\times 100$.

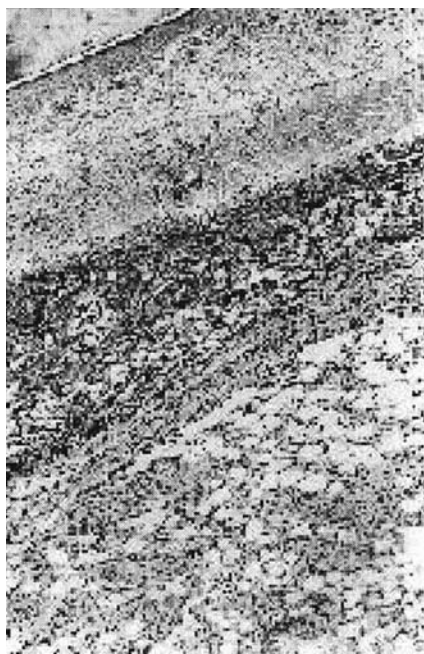

FIG. 6. Photomicrography of specimen irradiated by $\lambda 685$ nm laser (15 mW). It observed complete re-epithelization below the crust. Hyperemia is observed at the surface. Presence of dense connective tissue. Deeper on the wound it was observed the presence of adypocytes. H&E, approx. $\times 50$.

$\lambda 670$ or $\lambda 685$ nm, were used with the same dose (10 J/cm^2) and varied intensities (2, 15, and 25 mW). This study was designed to verify whether or not variation of the intensity and wavelength interfere with the healing process of cutaneous wounds.

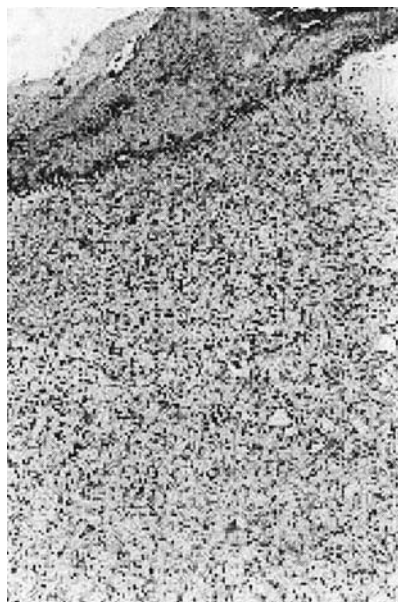

FIG. 7. Photomicrography of specimen irradiated by $\lambda 685$ nm laser (25 mW). A coagulated crust covers ulceration. Granulation tissue is characterized by fibroblastic proliferation and moderate mononuclear inflammatory infiltrate. H&E, approx. $\times 100$.

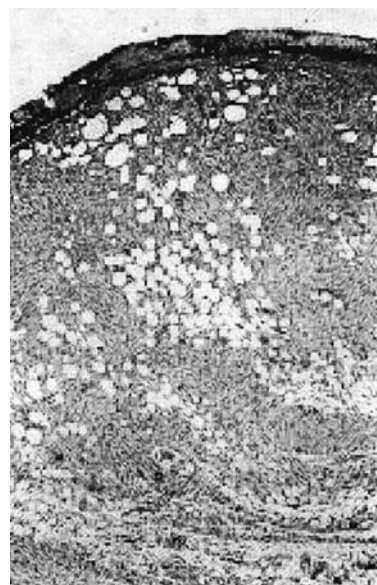


FIG. 8. Photomicrography of specimen irradiated by $\lambda 685$ nm laser (25 mW). Intense proliferation of adypocytes was observed at the wound surface. H&E, approx. $\times 100$.

In this study, it was evident that the healing process of non-irradiated animals followed the expected course of tissue repair. However, when LLLT was used, more advanced repair was detectable at the end of the experimental period. Many previous reports published have shown positive effects of LLLT on the healing process of both incisional and excisional wounds.²⁴ *In vitro*^{8,25,26} and *in vivo*¹¹ studies described elsewhere further support a positive biomodulatory effect of this modality of treatment. However, LLLT effects at cellular level are not fully understood,^{20,13} as controversial data concerning effectiveness of LLLT on the biomodulation of the healing process have been reported.^{27,17} While most *in vitro* experiments support the hypothesis that LLLT is able to accelerate the healing process,^{5,7-11,18,23,28-30} some failed to find any beneficial effect or found no effect on the healing process.^{13,31-33}

Our results indicate that LLLT causes a positive biomodulation of the healing process.^{19,26} The use of lower intensity (2 mW), independent of the wavelength, resulted in an accentuated amount of granulation tissue being associated with increased neovascularization and hyperemia when compared to the controls. Although inflammation was less intensely observed than in the controls, it was similar for both wavelengths. This suggests an anti-inflammatory effect of the treatment. The effect of LLLT is not a true anti-inflammatory as it does not prevent inflammation to occur but it triggered an early onset which was solved more quickly than on the controls as shown in previous reports.^{6,28,30} Another important result of LLLT was the presence of intense fibroblastic proliferation in the irradiated groups when compared to non-irradiated subjects. This has been shown in previous studies that also indicated increased fibroblastic activity in both *in vivo*¹¹ and *in vitro* conditions.^{8,6,13,34}

While on wounds irradiated with $\lambda 670$ nm laser an even distribution of both young and mature cells was detectable, in subjects irradiated with $\lambda 685$ nm laser there was a more promi-

ment number of young cells. This suggests a more advanced healing occurs when specimens are irradiated with $\lambda 670$ nm and provides strong evidence of the influence of the wavelength on the repair. The effect of LLLT was also confirmed by the presence of a smaller number of fibroblasts on non-irradiated specimens. Interestingly, it seems that the use of the $\lambda 685$ nm laser light results in a slower effect on the fibroblastic proliferation as a higher number of young cells were observed when this wavelength was used. This corroborates previous studies in which it was suggested that the use of shorter wavelengths present better results.¹¹

Increasing intensity to 15 mW resulted in more intense neovascularization than their controls since this aspect is strongly associated with intense fibroblastic proliferation. This result represents a positive effect of LLLT on endothelial cells and increased release of several mediators of cellular proliferation.^{8,15,17,20,29} Our results also confirmed previous reports that lower wavelengths have stronger effects on both collagen deposition and distribution as the presence of a connective tissue rich on collagen fibers was markedly present when $\lambda 670$ nm laser light was used.^{8,25,34,35}

Inflammation was less intense and more advanced on irradiated wounds than in their controls and it was less intense when $\lambda 670$ nm laser was used. Similarly this was observed when 2 mW was used, which is explained by the early onset of the inflammatory response when shorter wavelengths are used.^{6,12,14}

Additional increase of the intensity to 25mW caused differences between irradiated and non-irradiated groups. Re-epithelialization was more advanced when LLLT was used. The use of $\lambda 670$ nm laser light resulted in re-epithelialization of the dermis and the presence of dense conjunctive tissue. However, when the wounds were irradiated with $\lambda 685$ nm, there were still remains of vascular granulation tissue and discreet hyperemia. Granulation tissue was characterized by an intense proliferation of mature fibroblasts on wounds irradiated with $\lambda 670$ nm laser and by young fibroblasts in $\lambda 685$ nm irradiated subjects, who also presented increased amounts of mononuclear inflammatory cells. This also suggests the influence of the wavelength on the repair, as shorter wavelengths resulted in a more rapid healing process.^{34,6}

A different and not yet reported feature observed in this group was the intense presence of typical adipocytes on specimens irradiated with $\lambda 685$ nm laser light. These cells were located close to the wound surface, and this superficial location is not typical for this type of cells. This finding warrants further investigation.

Further evidence of the effect of both the intensity and wavelength on the repair of the wounds was found within the irradiated groups. When $\lambda 670$ nm laser was used, neovascularization was intense on all the three subgroups. Hyperemia was also present in all subgroups but somewhat less intense when 25 mW was used. The specimens irradiated with 25 mW presented a poorly vascularized granulation tissue.

The mononuclear inflammatory infiltrate was discreet with 2 and 25 mW, which was more intense than that produced by 15 mW. Fibroblastic proliferation was more intense when 2 and 25 mW were used. Re-epithelialization was discreet in all subgroups.

The use of $\lambda 685$ nm laser light on subgroups 2 and 15 mW resulted in the presence of a diffuse and moderate mononuclear inflammatory infiltrate, which was more intense when 25 mW

was used, despite hyperemia being more intense when 15 mW was used. Although fibroblastic proliferation was considerable in all the intensities, with 2 and 25 mW, the presence of young cells was marked, and with 15 mW, mature cells prevailed.

Visible lasers have been the most widely used for wound healing, but, the development of low costs diode lasers have provided a new option for treatment of these wounds. Previous studies showed differences of effects between close wavelengths.¹¹ Al-Watban et al.¹¹ observed the effects of different wavelengths on the healing process and evaluated the transmission of the laser light throughout the skin, suggesting that $\lambda 632$ nm laser light (20 J/cm²) was more effective than the other wavelengths used and the increase of transmission of the laser light throughout the skin is not related to biomodulation.

These preliminary results indicate that LLLT improved cutaneous wound repair and that the effect is a result of an inversely proportional relationship between wavelength and intensity. The treatment is more effective combining higher intensity with short wavelength or lower intensity with higher wavelength.

REFERENCES

1. Brasileiro, F.G., Pereira, F.E.L., Pittela, J.E.H., et al. (1993). *Bogliolo patologia geral*. Rio de Janeiro: Guanabara Koogan S.A.
2. Martin, P. (1997). Wound healing—aiming for perfect skin regeneration. *Science* 276, 75–81.
3. Cotran, R., Kumar, V., and Collins, T. (2000). *Robbins patologia estrutural e funcional*. Rio de Janeiro: Guanabara Koogan.
4. Clark, R.A.F., and Henson, P.M. (1988). *The molecular and cellular biology of wound repair*. New York: Plenum Press.
5. Romanos, G.E., Pelekanos, S., and Strub, J.-R. (1995). Effects of Nd:YAG laser on wound healing processes: clinical and immunohistochemical findings in rat skin. *Lasers Surg. Med.* 16, 368–379.
6. Rigau, I. (1996). Acción de la luz laser a baja intensidad en la modulación de la función celular [M.D. dissertation]. Universitat Rovira i Virgili.
7. Halcin, C.H., and Uitto, J. (1997). *Biologic effects of low-energy lasers*. Philadelphia: Lippincott-Raven.
8. Hallman, H.O., Basford, J.R., O'Brien, J.F., et al. (1998). Does low-energy helium-neon laser irradiation alter "in vitro" replication of human fibroblasts? *Lasers Surg. Med.* 8, 125–129.
9. Ghamsari, S.M., Taguchi, K., Abe, N., et al. (1996). Histopathological effect of low-level laser therapy on sutured wounds of the teat in dairy cattle. *Vet. Q.* 18, 17–21.
10. Simunovic, Z., Ivankovich, A.D., and Depolo, A. (2000). Wound healing of animal and human body sport and traffic accident injuries using low-level laser therapy treatment: a randomized clinical study of seventy-four patients with control group. *J. Clin. Laser Med. Surg.* 18, 67–73.
11. Al-Watban, F.A.H., and Zhang, X.Y. (2001). The acceleration of wound healing is not attributed to laser skin transmission. *Laser Ther.* 6–11.
12. Basford, J. (1995). Low intensity laser therapy: still not an established clinical tool. *Lasers Surg. Med.* 16, 331–342.
13. Allendorf, J.D.F., Bessler, M., Huang, J., et al. (1997). Helium-neon laser irradiation at fluences of 1,2, and 4J/cm² failed to accelerate wound healing as assessed by both wound contracture rate and tensile strength. *Lasers Surg. Med.* 20, 340–345.
14. Pinheiro, A.L.B. (1998). *Interação tecidual—lasers cirúrgicos*. São Paulo: Pancast.
15. Karu, T., Pyatibrat, I., and Kalendo, G. (1995). Irradiation with He-Ne laser increases ATP level in cells cultivated *in vitro*. *J. Photoc. Photob. B. Biol.* 27, 219–223.

16. Conlan, M.J., Rapley, J.W., and Cobb, C.M. (1996). Biostimulation of wound healing by low-energy laser irradiation. A review. *J. Clin. Periodontol.* 23, 492–496.
17. Karu, T. (2000). Mechanisms of low-power laser light action on cellular level. *Lasers Med. Dentistry*. Ed. By Z. Simunovic, Vitgraf: Rijeka. 97–125.
18. Almeida, L.L., and Brugnera, A. (1998). Aplicações Clínicas do Laser Não-Cirúrgico. In, *J. Lasers na Odontologia Moderna*. São Paulo: Pancast. 99–120.
19. Braverman, B., McCarthy, R.I., Ivankovich, A.D., et al. (1989). Effect of helium-neon and infrared laser irradiation on wound healing in rabbits. *Lasers Surg. Med.* 9, 50–58.
20. Abergel, R.P., Meeker, C.A., Lam, S.T., et al. (1984). Control of connective tissue metabolism by lasers: Recent developments and future prospects. *J. Am. Acad. Dermatol.* 11, 1142–1150.
21. Yu, W., Naim, J.O., and Lanzafame, R.J. (1997). Effects of photostimulation on wound healing in diabetic mice. *Lasers Surg. Med.* 20, 56–63.
22. Grossman, N., Schneid, N., Reuveni, H., et al. (1998). 780 nm low power diode laser irradiation stimulates proliferation of keratinocyte cultures: Involvement of reactive oxygen species. *Lasers Surg. Med.* 22, 212–218.
23. Fiszerman, R., and Markmann, C.A. (2000). Effect of low laser therapy on chronic diabetic foot ulcers. In: *American Diabetes Association, Inc. ABSTRACT BOOK: 60th Scientific Sessions*. Abstract 1656-PO. Supl. 1, 49, A393.
24. Walker, M.D., Rumpf, S., Baxter, G.D., et al. (2000). Effect of low-intensity laser irradiation (660nm) on a radiation-impaired wound-healing model in murine skin. *Lasers Surg. Med.* 26, 41–47.
25. Webb, C., Dyson, M., and Lewis, W.H.P. (1998). Stimulatory effect of 660nm low level laser energy on hypertrophic scar-derived fibroblasts: Possible mechanisms for increase in cell counts. *Lasers Surg. Med.* 22, 294–301.
26. Houghton, P.E., and Brown, J.L. (2001). Effect of low level laser on healing in wounded fetal mouse limbs. *Laser therapy*. 11, n. 2, 54–70.
27. Usuba, M., Akai, M., and Shirasaki, Y. (1998). Effect of low-level laser therapy (LLLT) on viscoelasticity of the contracted knee joint: Comparison with whirlpool treatment in rats. *Lasers Surg. Med.* 22, 81–85.
28. Tatarunas, A.C., Matera, J.M., and Dagli, M.L.Z. (1998). Estudo Clínico e Anatomopatológico da Cicatrização Cutânea no Gato Doméstico. *Utilização do Laser de Baixa Potência GAAS (904nm)*. *Acta Cir. Bras.* 13, n.2,.
29. Karu, T. (1999). Primary and secondary mechanisms of action of visible to near-IR radiation on cells. *J. Photoch. Photob. B. Biol.* 49, 1–17.
30. Al-Watban, F.A.H., Zhang, X.Y., and Andres, B.L. (2000). Wound healing efficacy of hene laser (632.8 nm) and pharmacological treatments in normal rats. *Lasers Life Sci.* 9, 245–254.
31. Kama, J.S., Hutschenreiter, G., Haina, D., et al. (1981). Effect of low-power density laser radiation on healing of open skin wounds in rats. *Arch. Surg.* 116, 293–296.
32. Petersen, S.L., Botes, C., Olivier, A., et al. (1999). The effect of low laser therapy (LLLT) on wound healing in horses. *Equine Vet. J.* 31, 228–231.
33. Schlager, A., Oehler, K., Huebner, K.-U., et al. (2000). Healing of burns after treatment with 670-nanometer low-power light. *Plas. Reconstruct. Surg.* 105, 1635–1639.
34. Soares, J.H., Tardivo, J.P., Goldenberg, S., et al. (1989). Aspectos morfológicos e histométricos da reparação tecidual das feridas cutâneas de ratos após irradiação com o laser de helio-neônio. *Acta Cir. Bras.* 4, 56–60.
35. Utsunomiya, T. (1998). A histological study of the effects of low-power laser irradiation on wound healing of exposed dental pulp tissues in dogs, with special reference to lectins and collagens. *J. Endo.* 24, 187–193.

Address reprint requests to:
Antonio Luiz B. Pinheiro, Ph.D.
Institute for Research and Development
Univap
Av. Shishima Hifumi, 2.911–Urbanova
São Jose dos Campos
São Paulo, 12244-000, Brazil

E-mail: pinheiro@univap.br